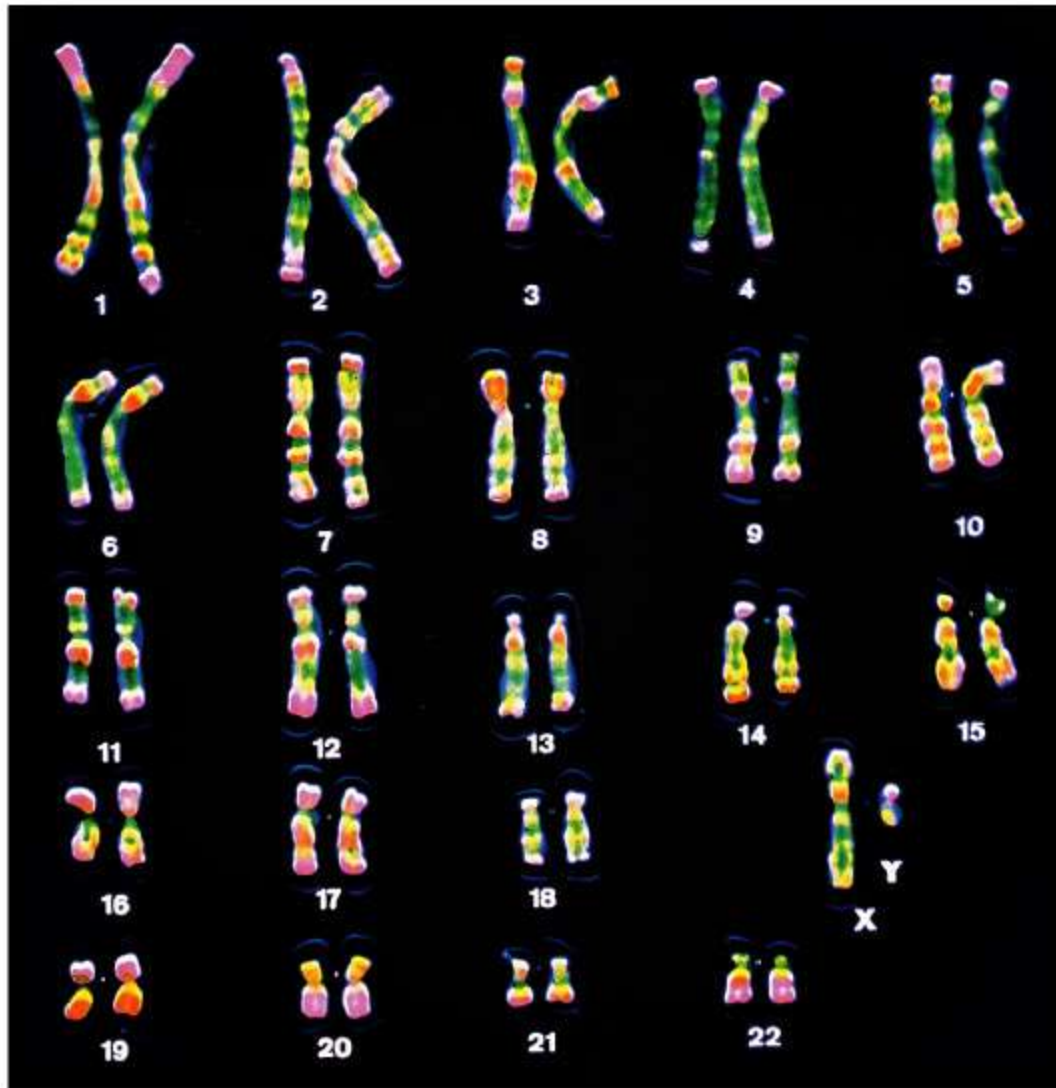
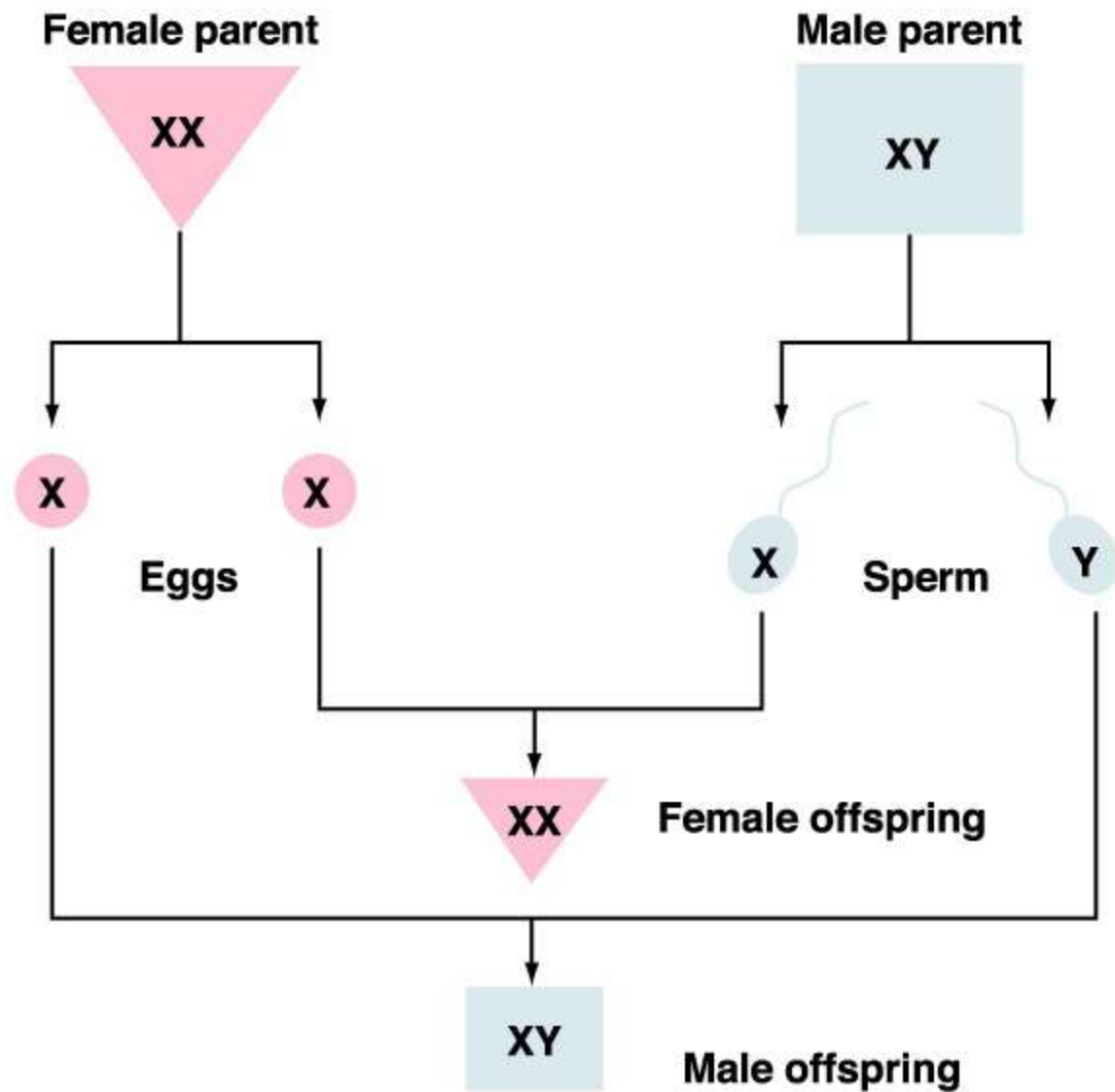


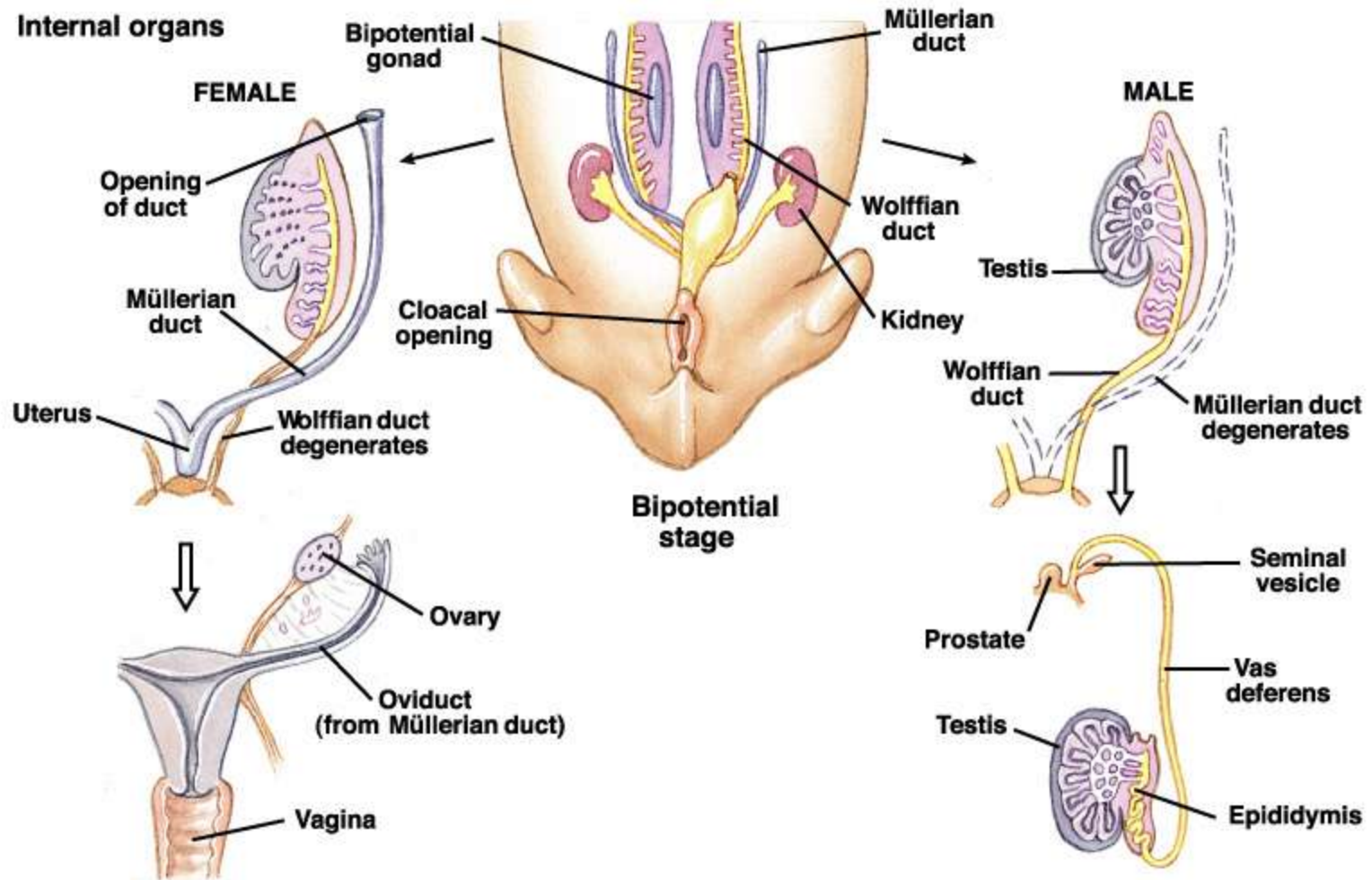


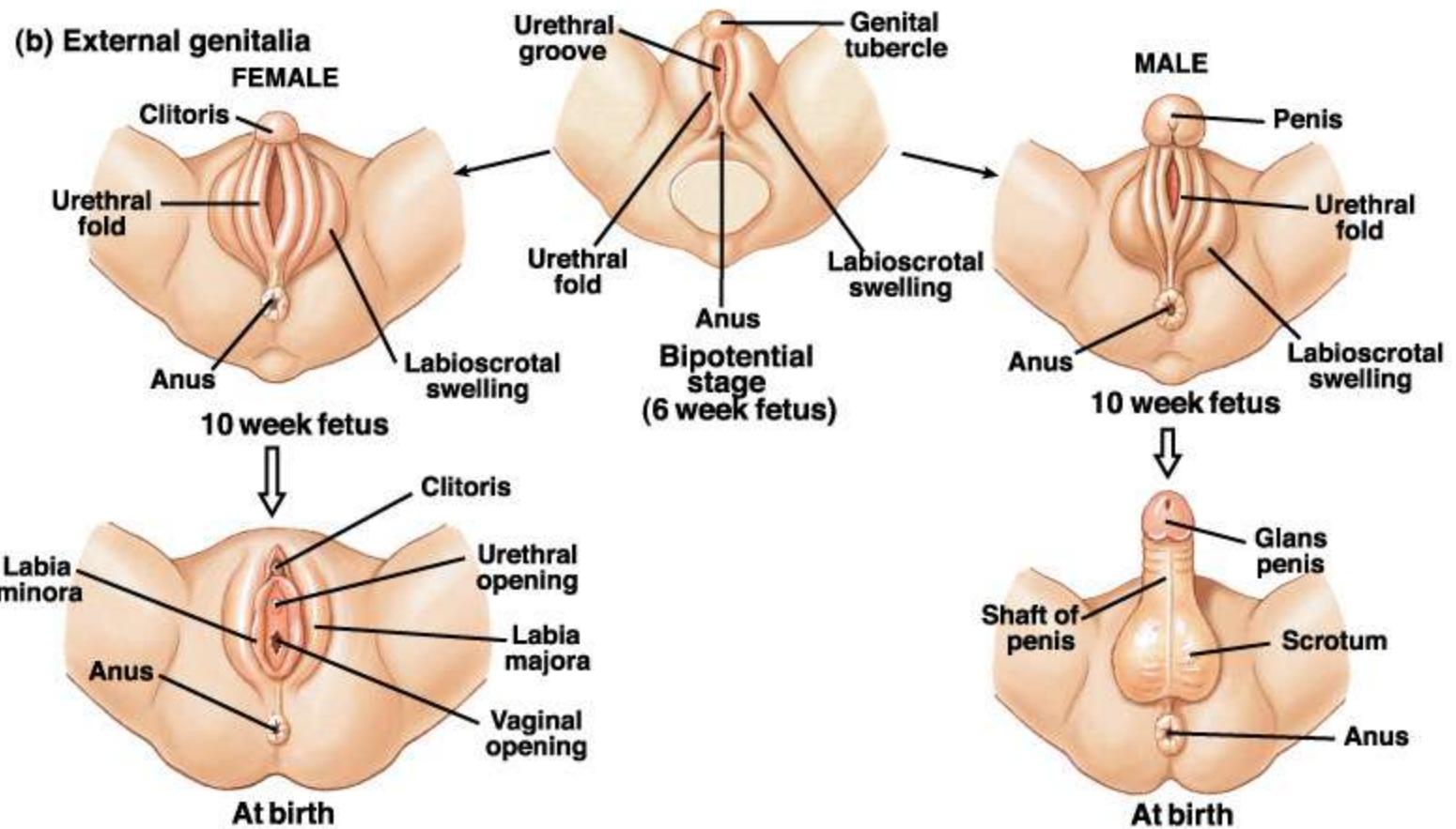
# REPRODUCTION

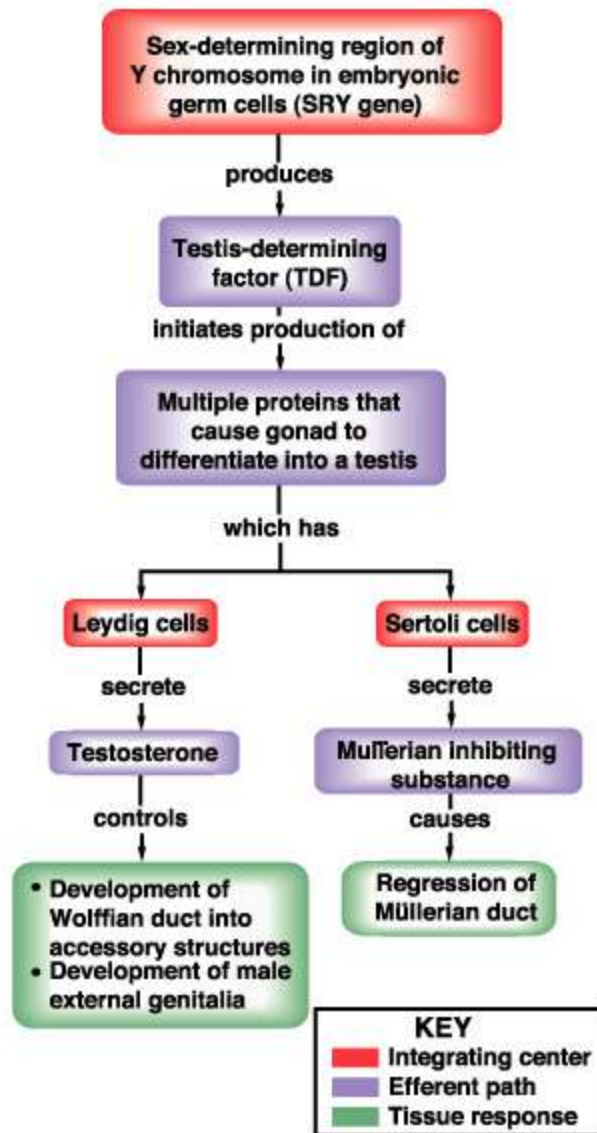




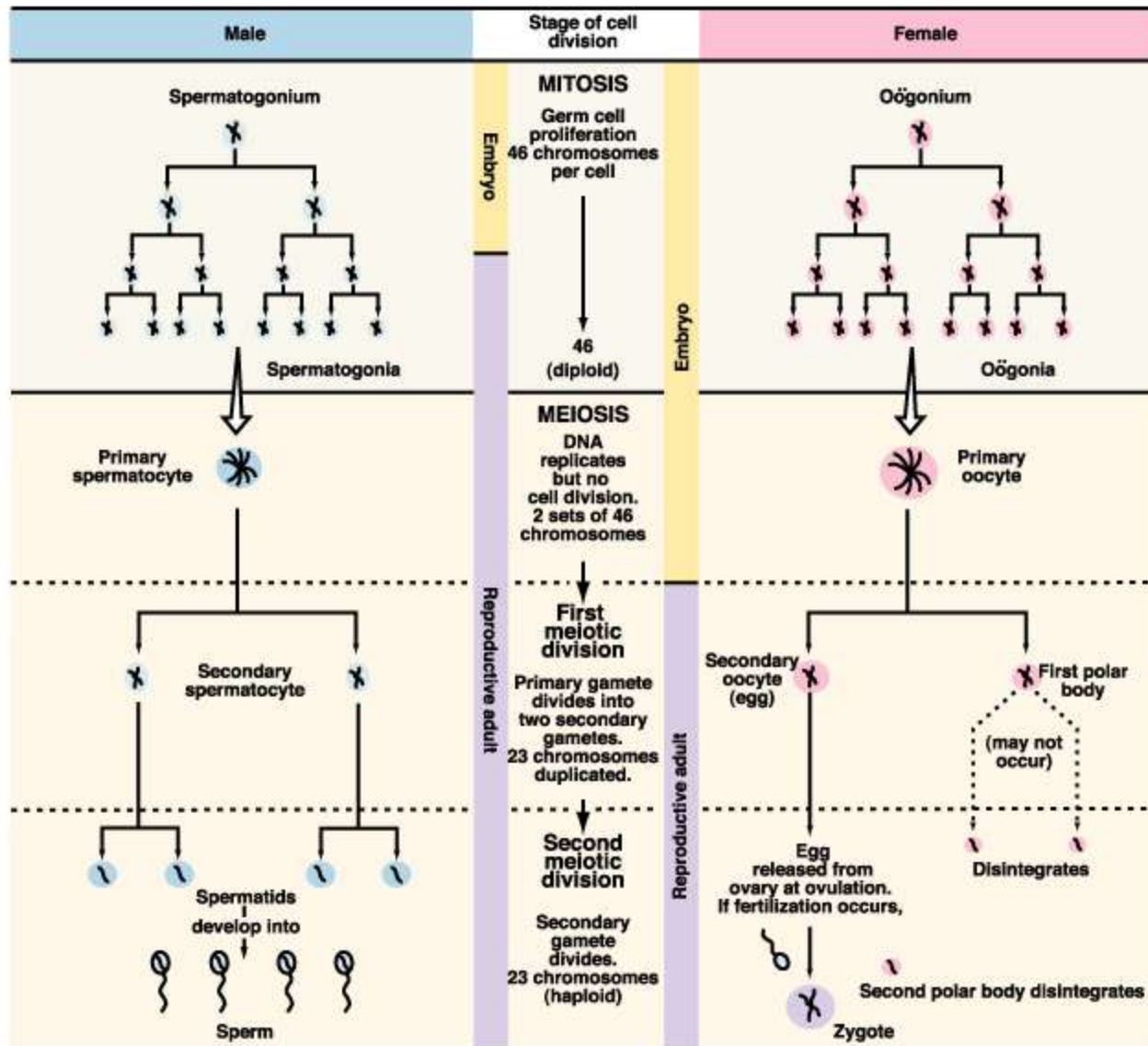
## Internal organs



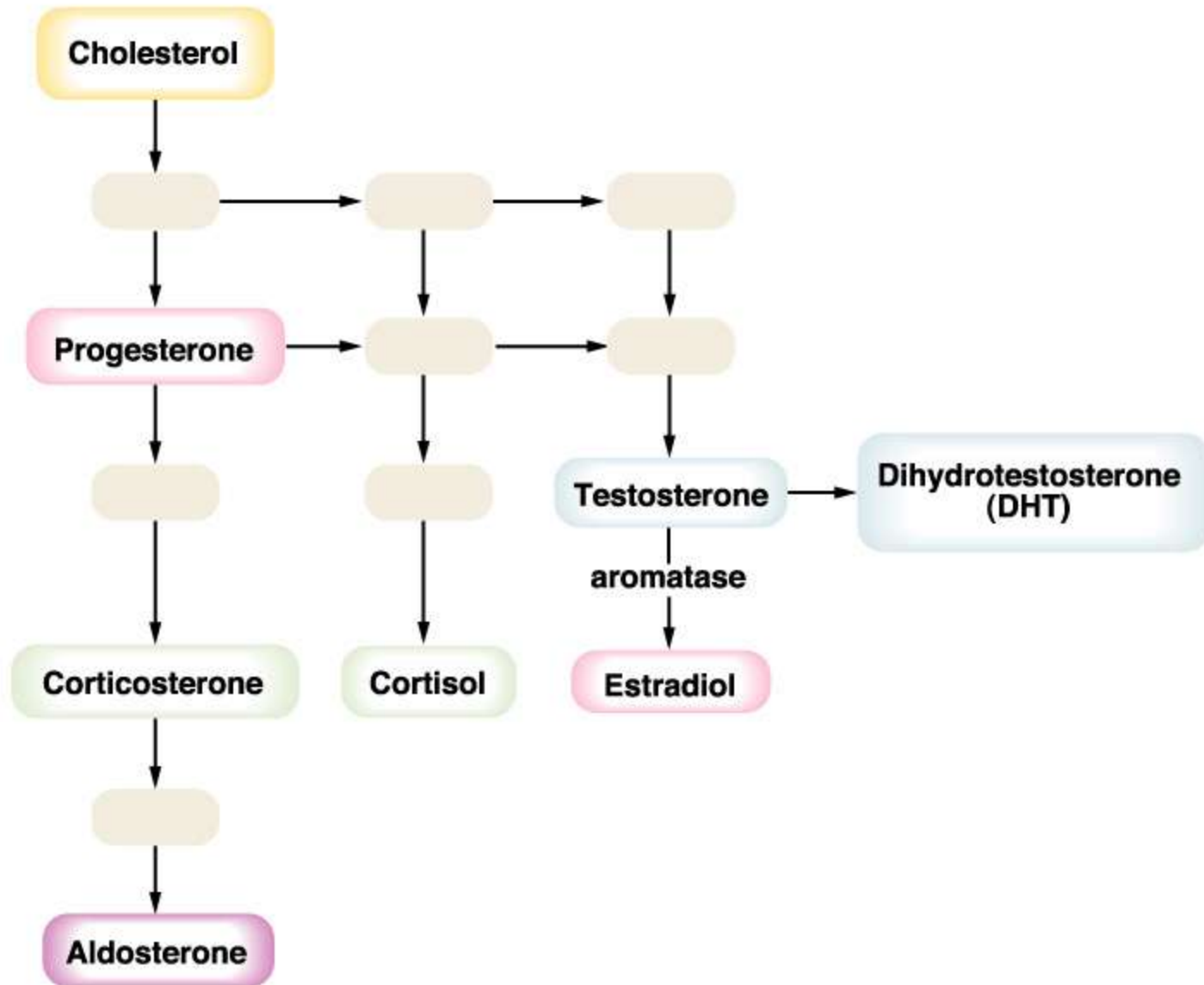


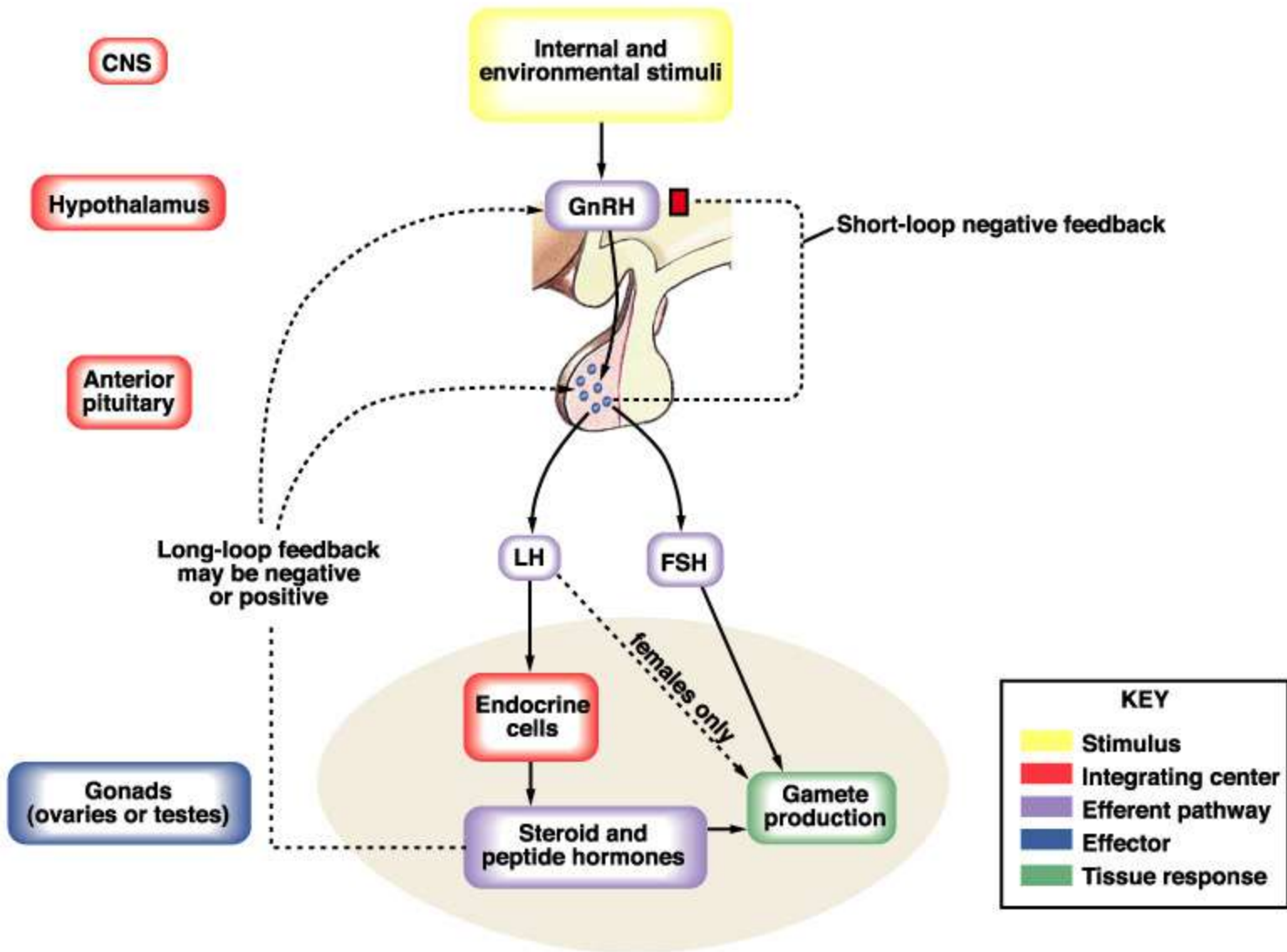


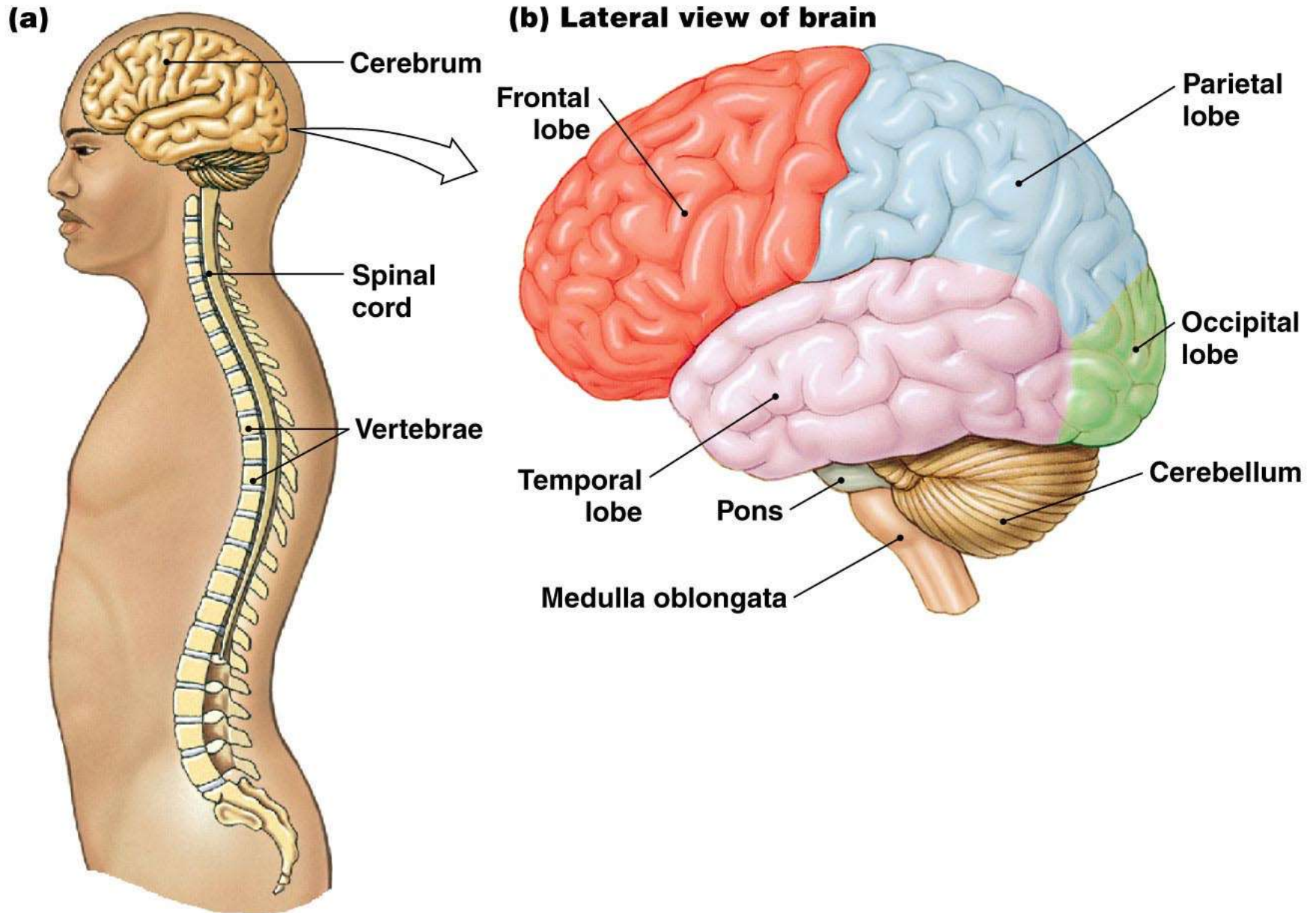




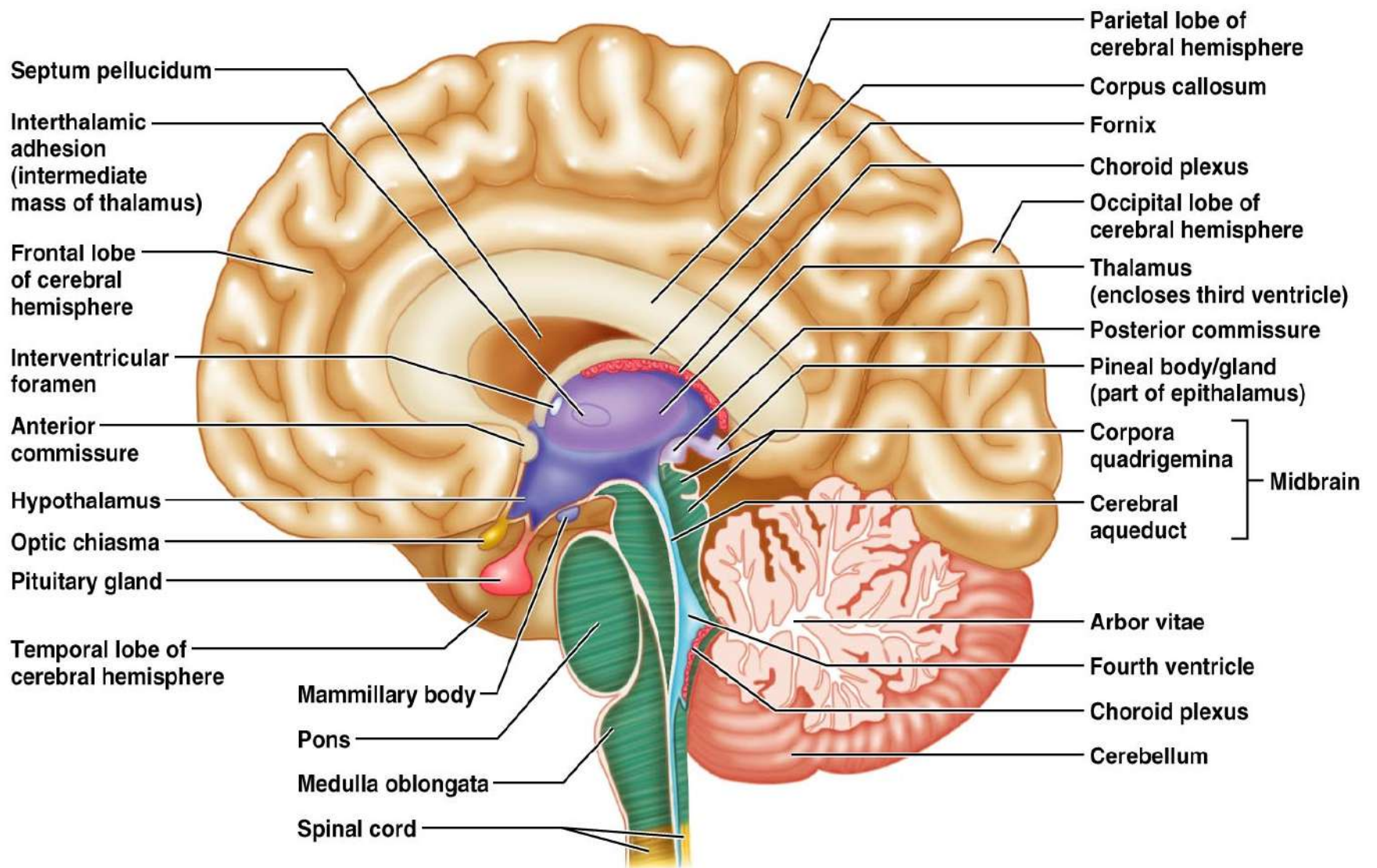




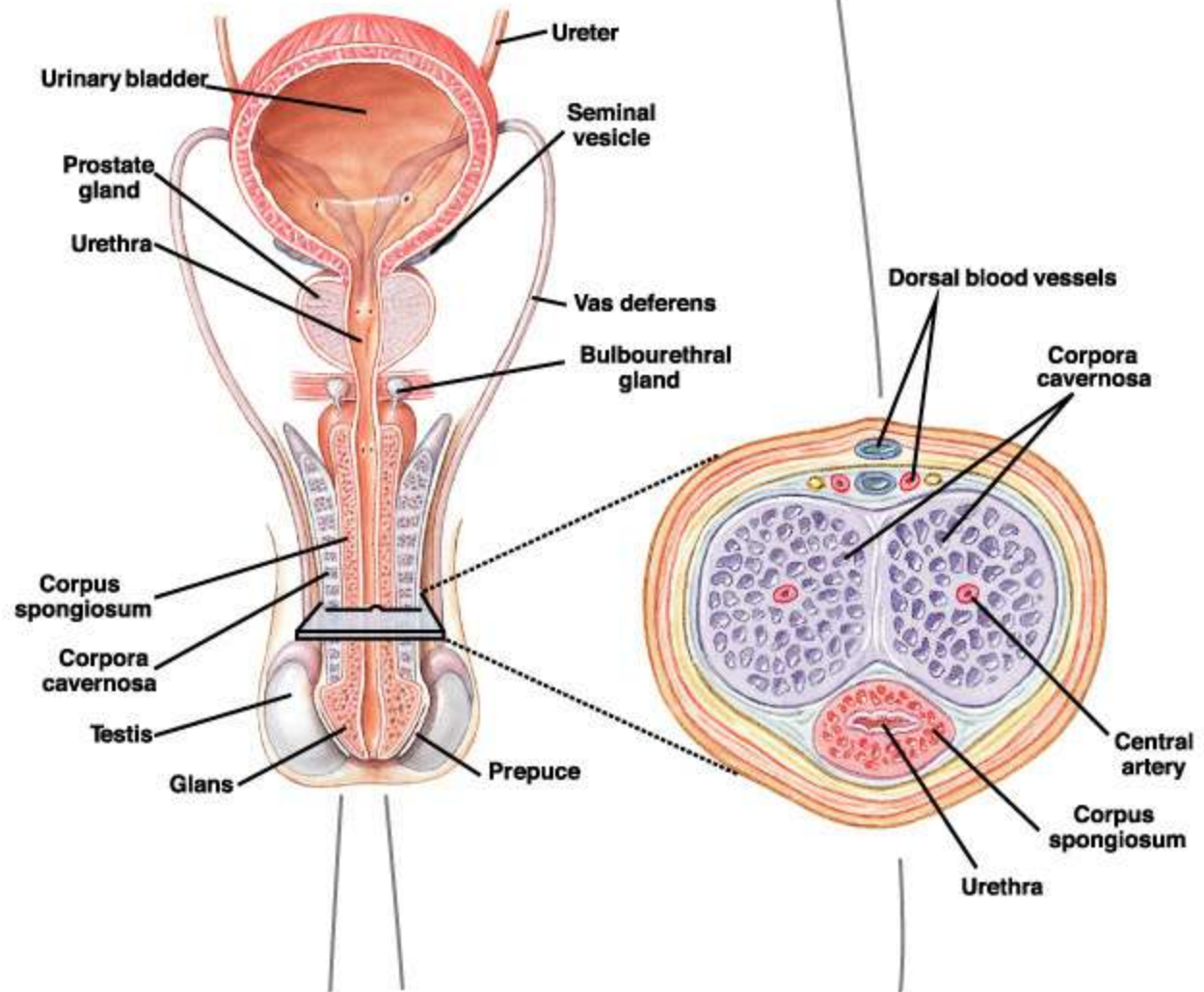


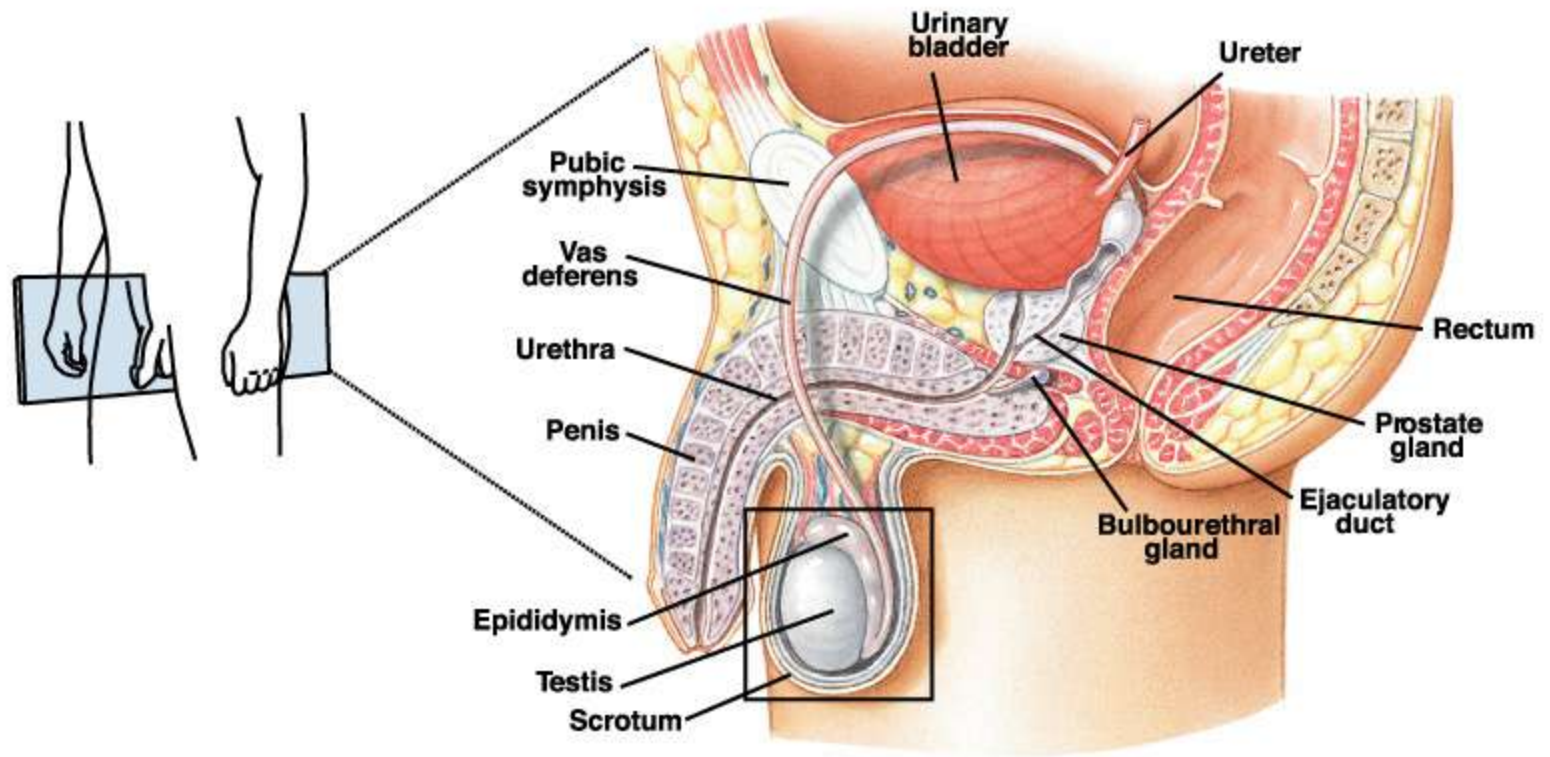


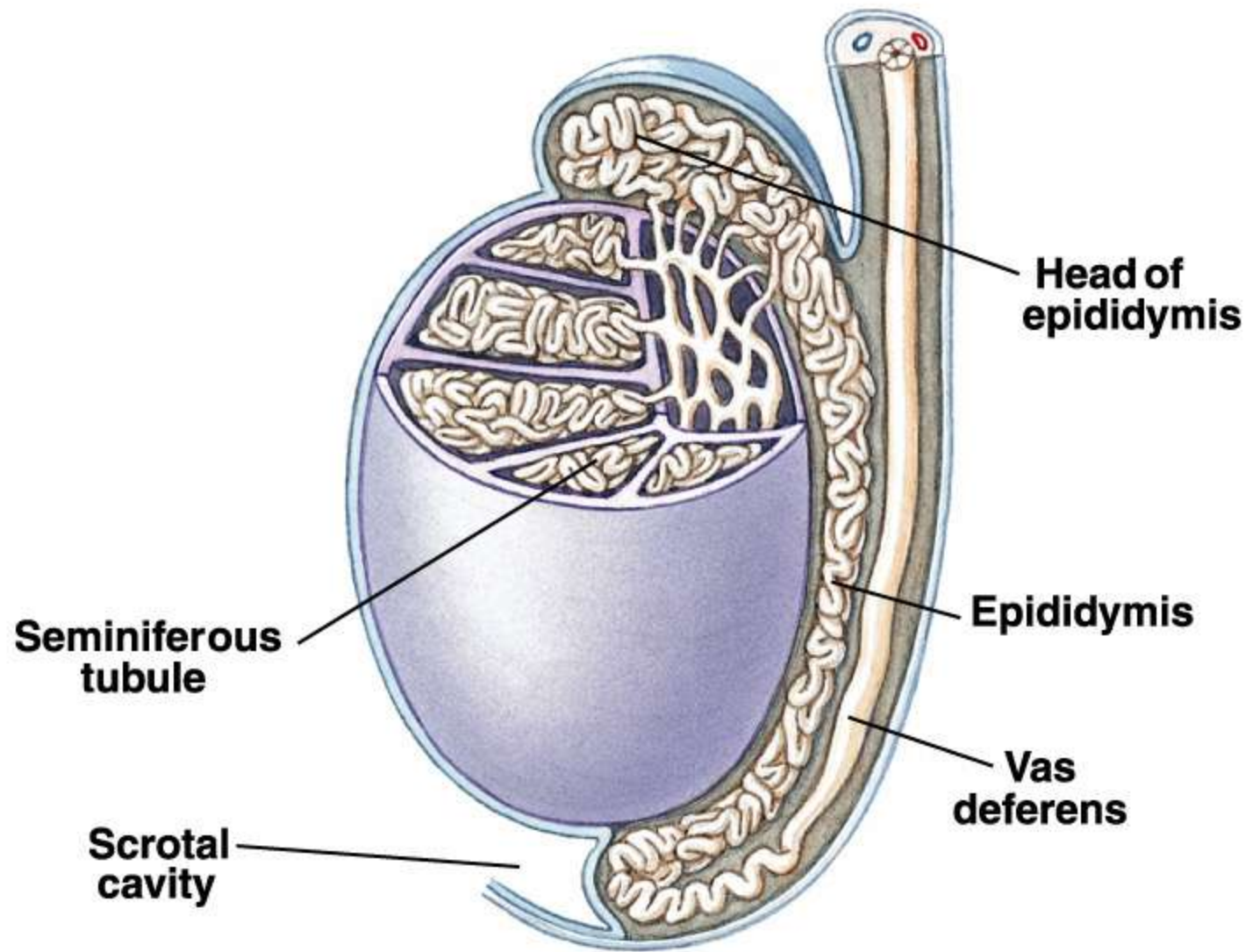
Copyright © 2007 Pearson Education, Inc., publishing as Benjamin Cummings.



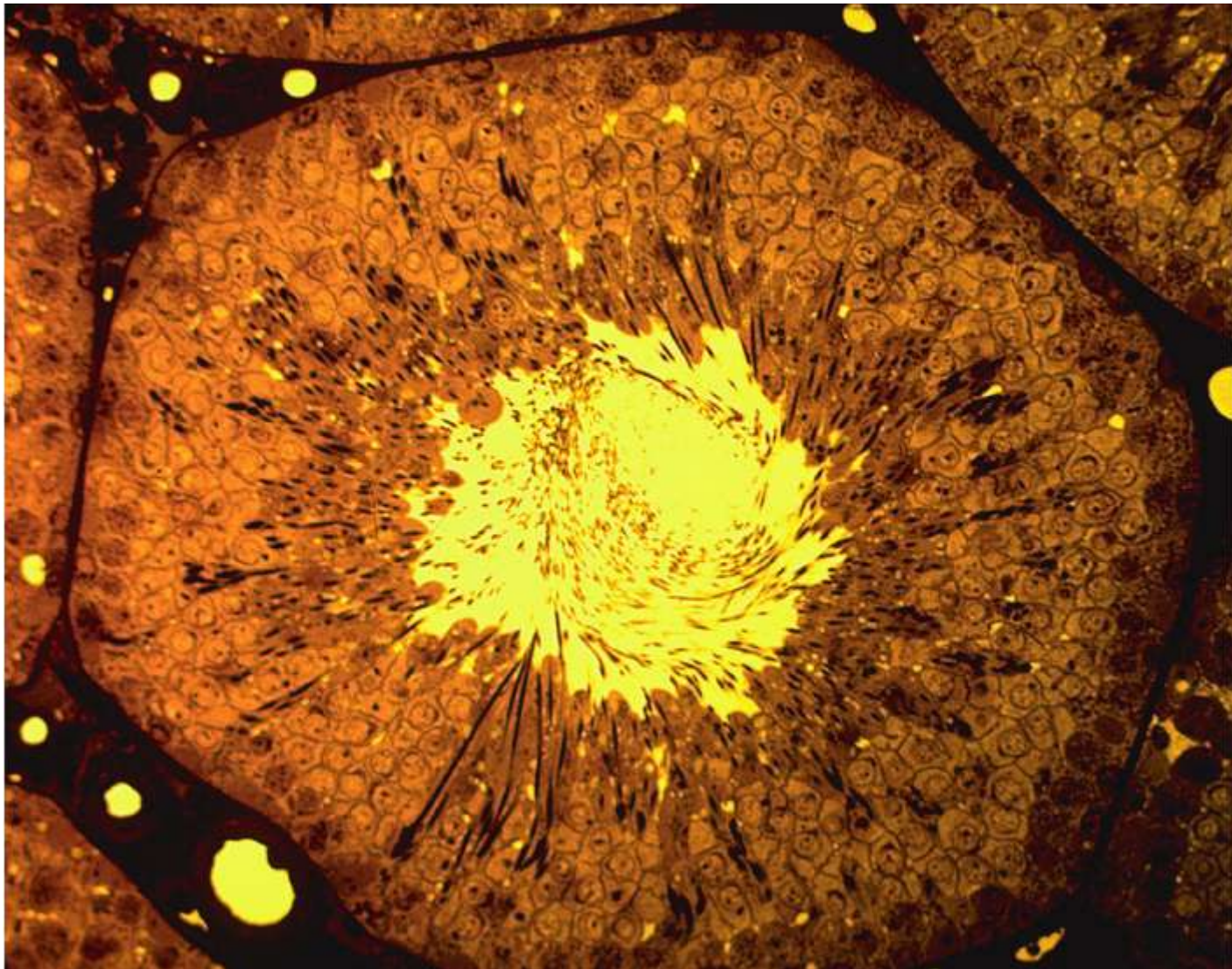


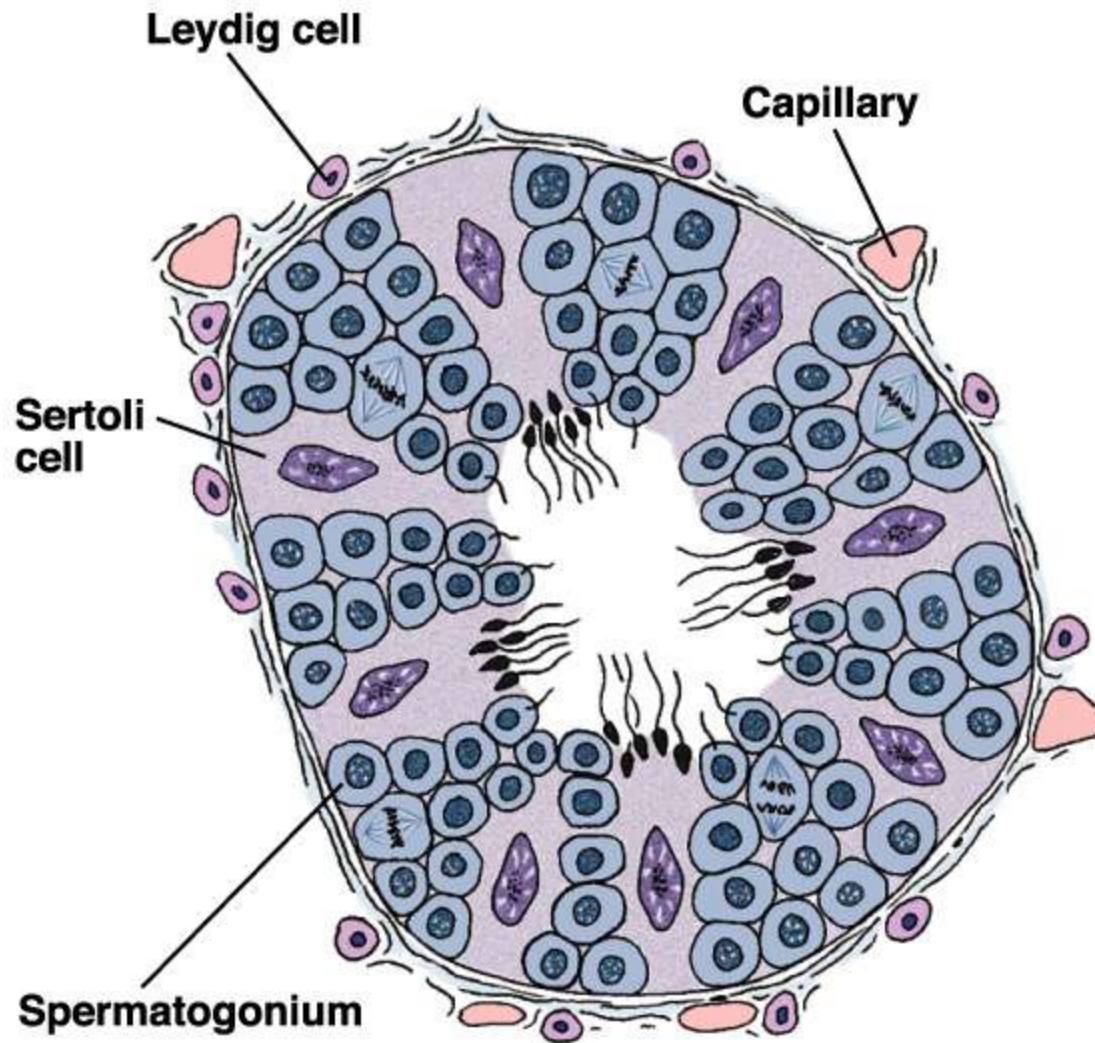




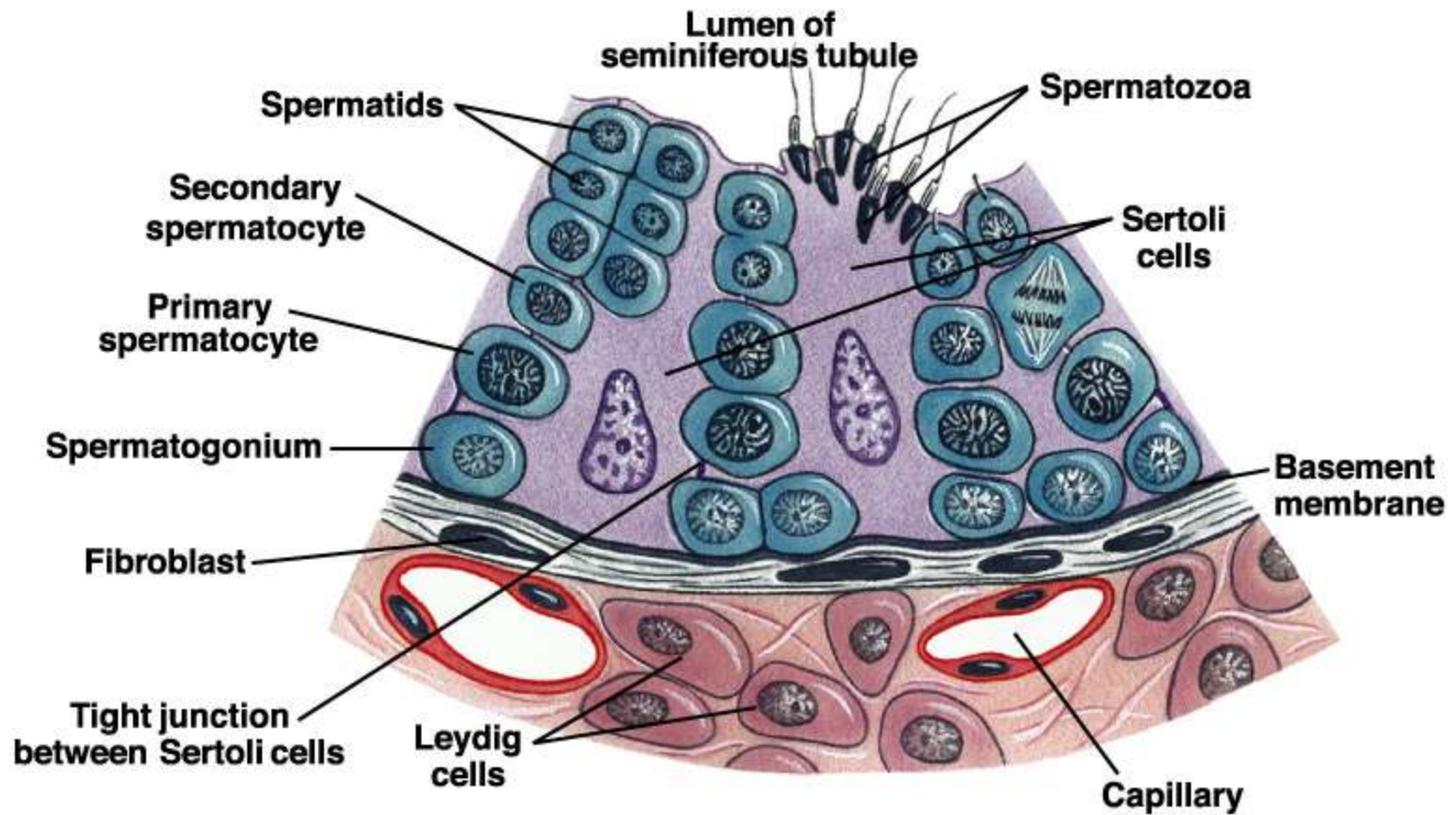


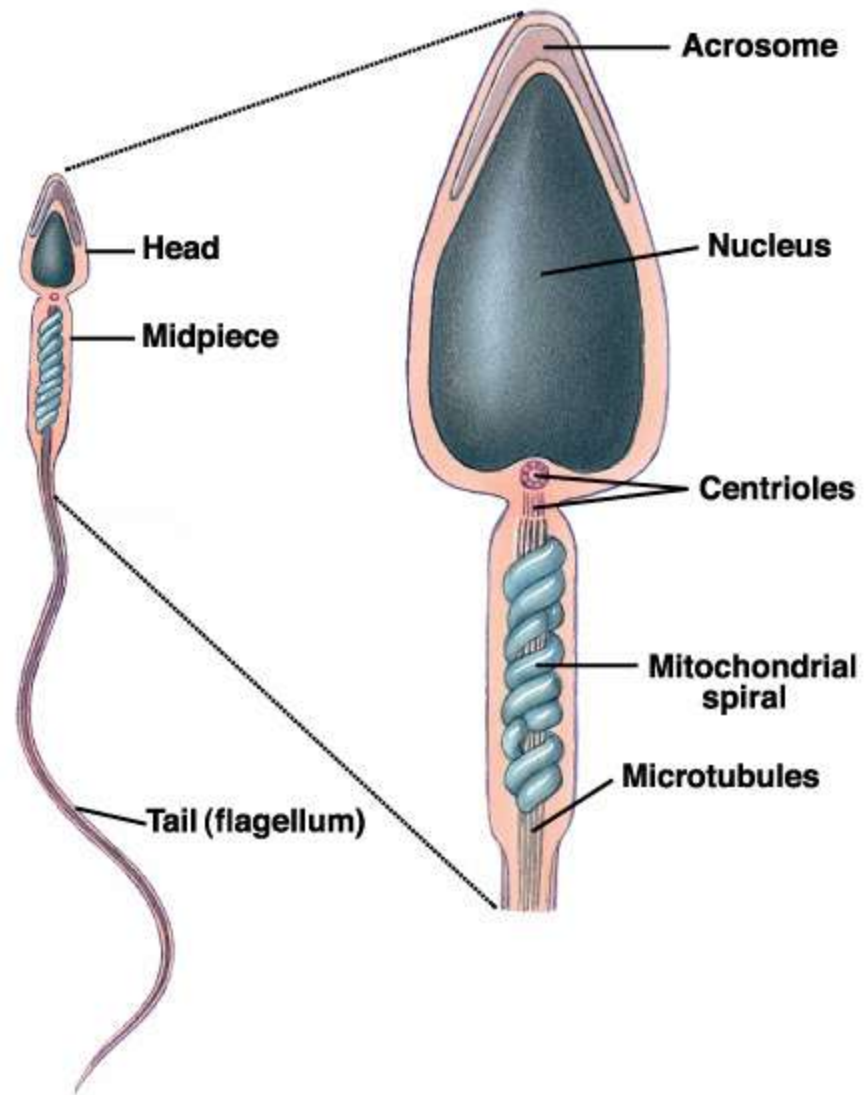


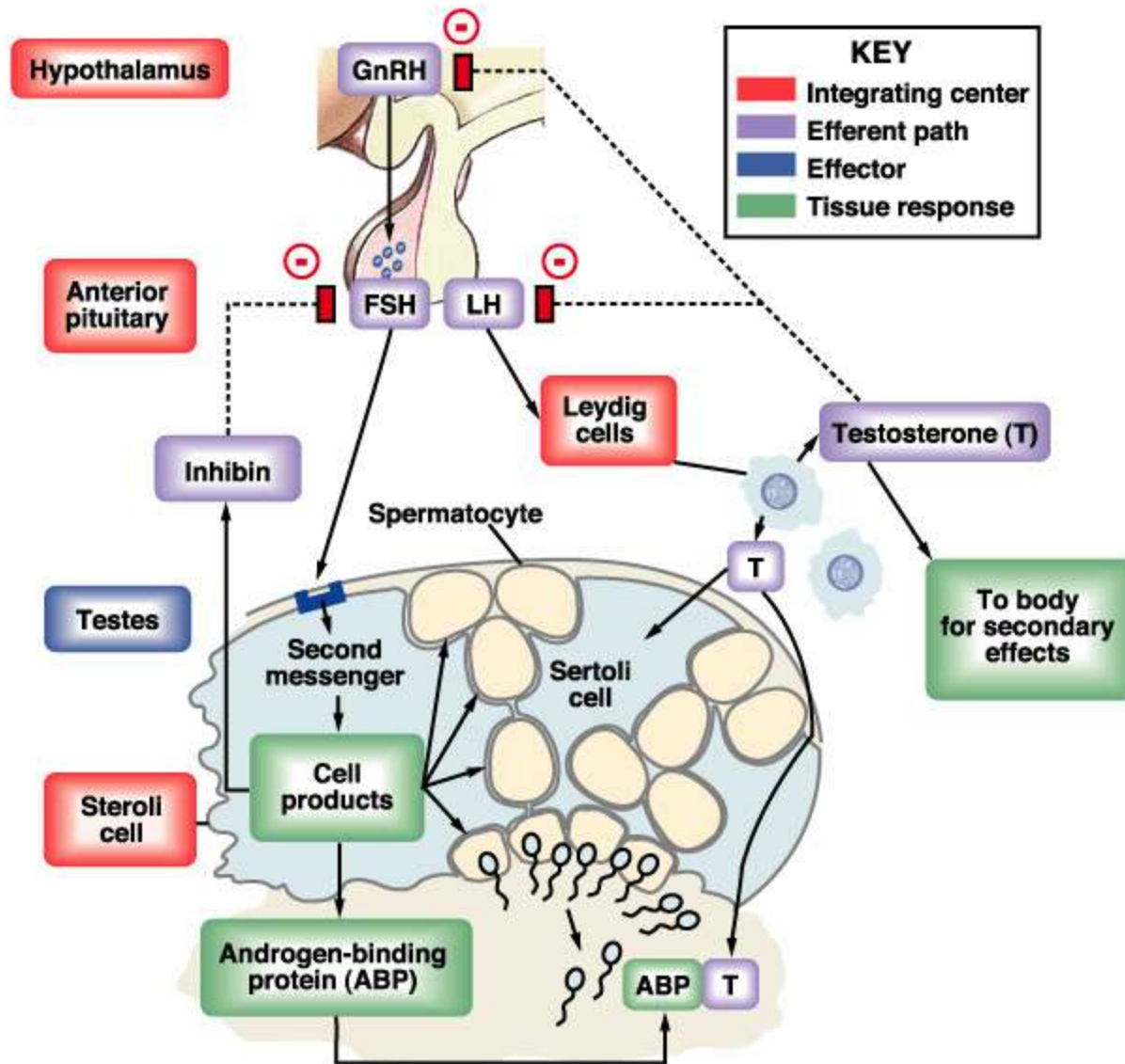


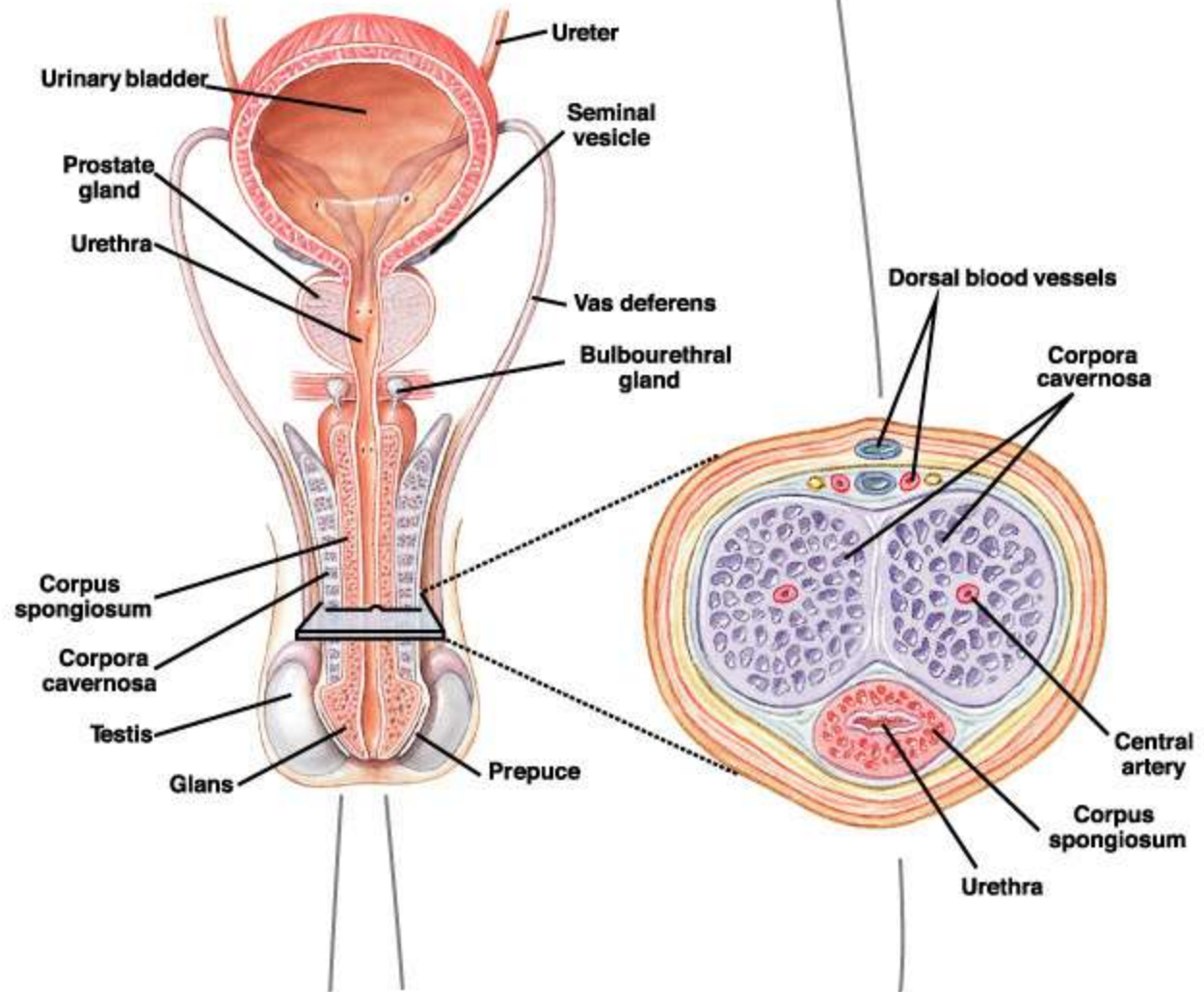




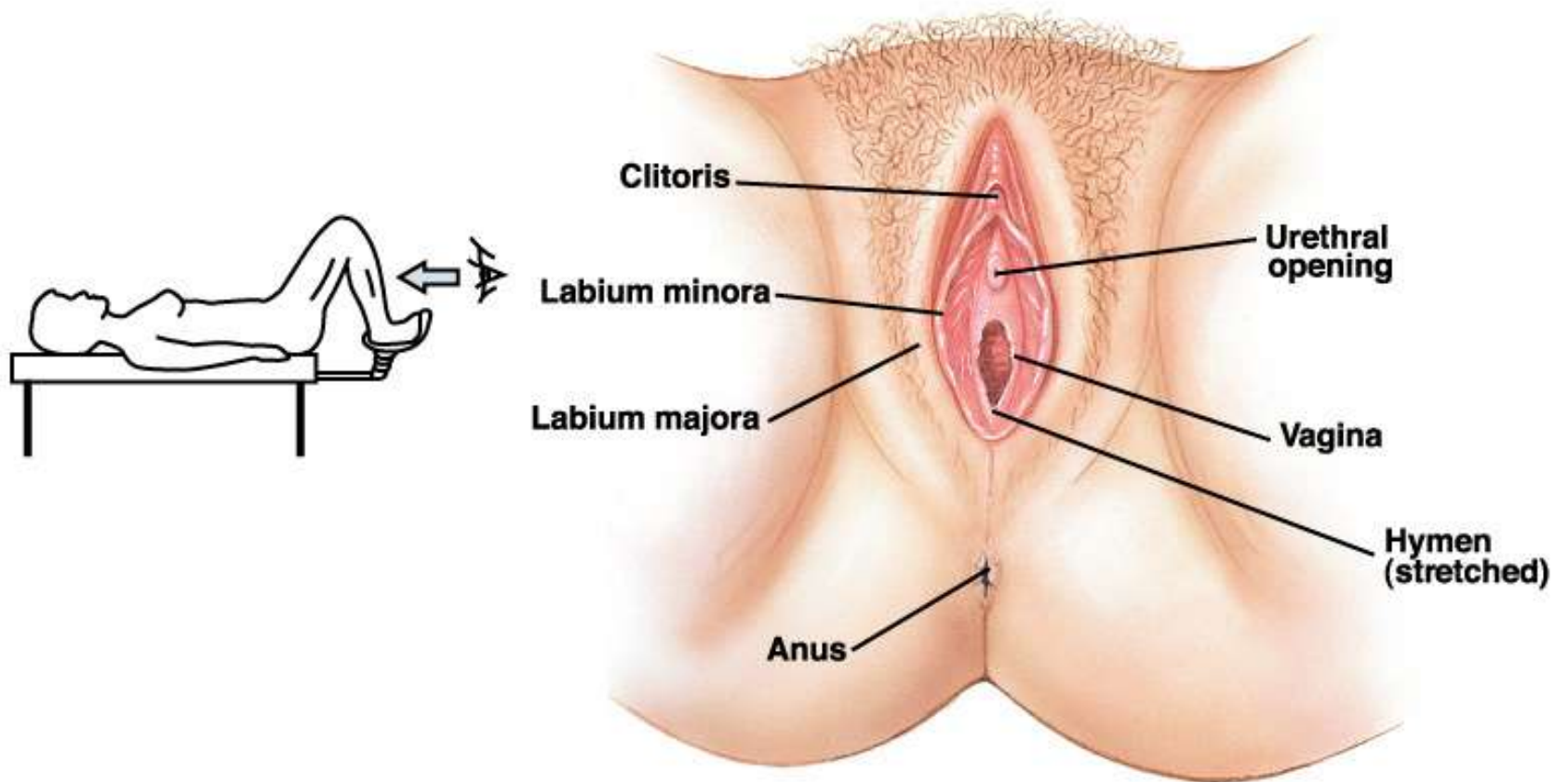




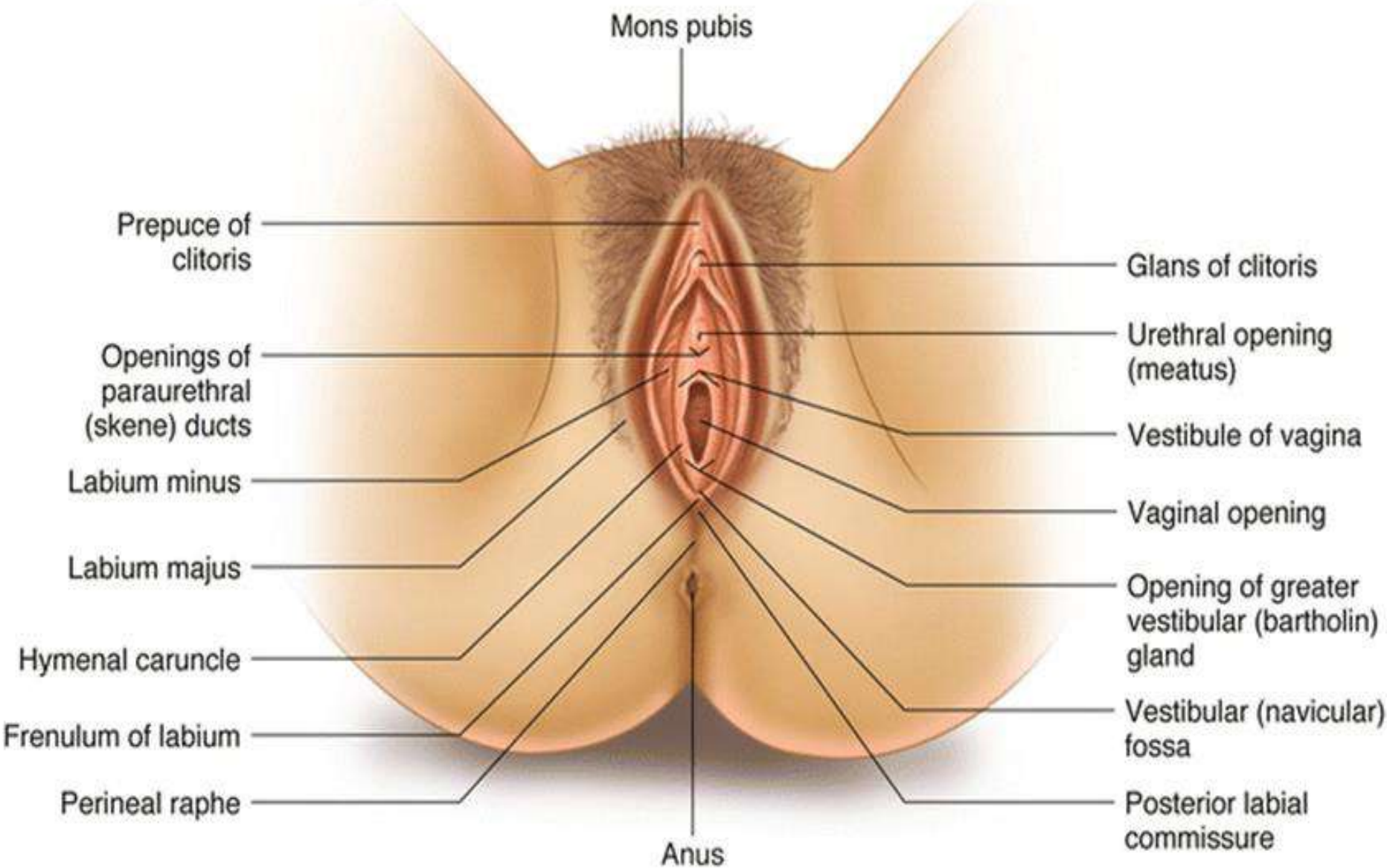


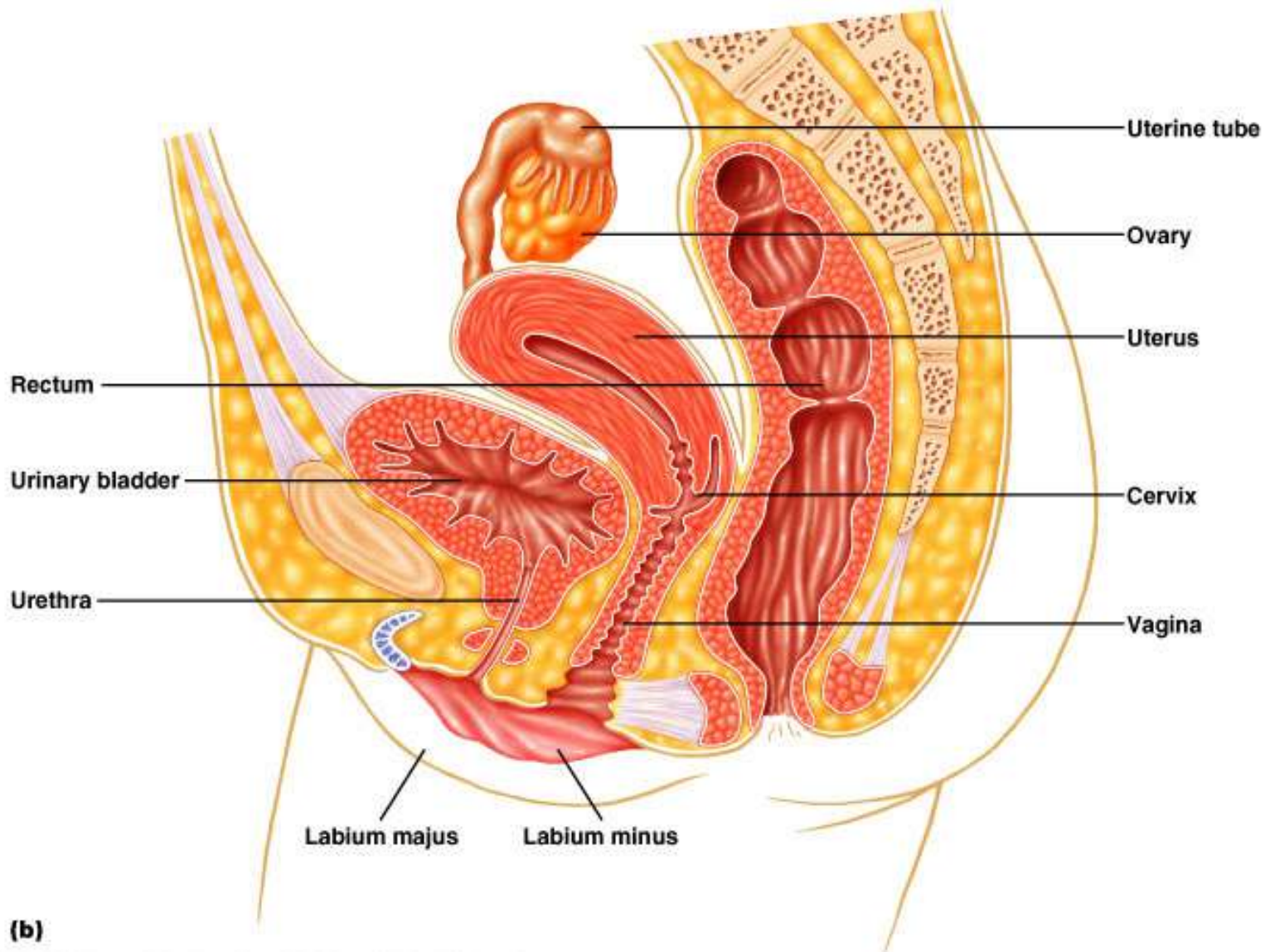




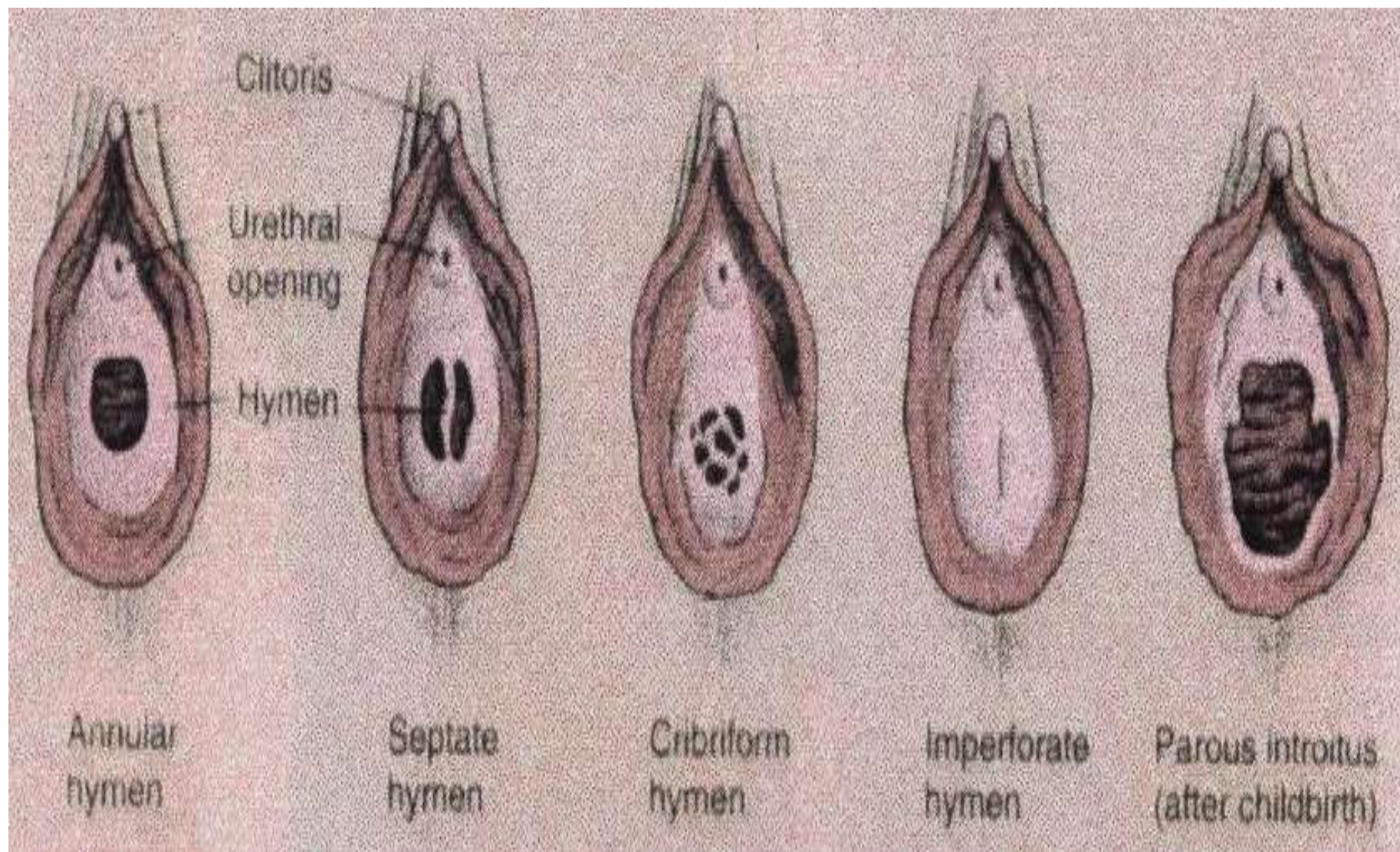


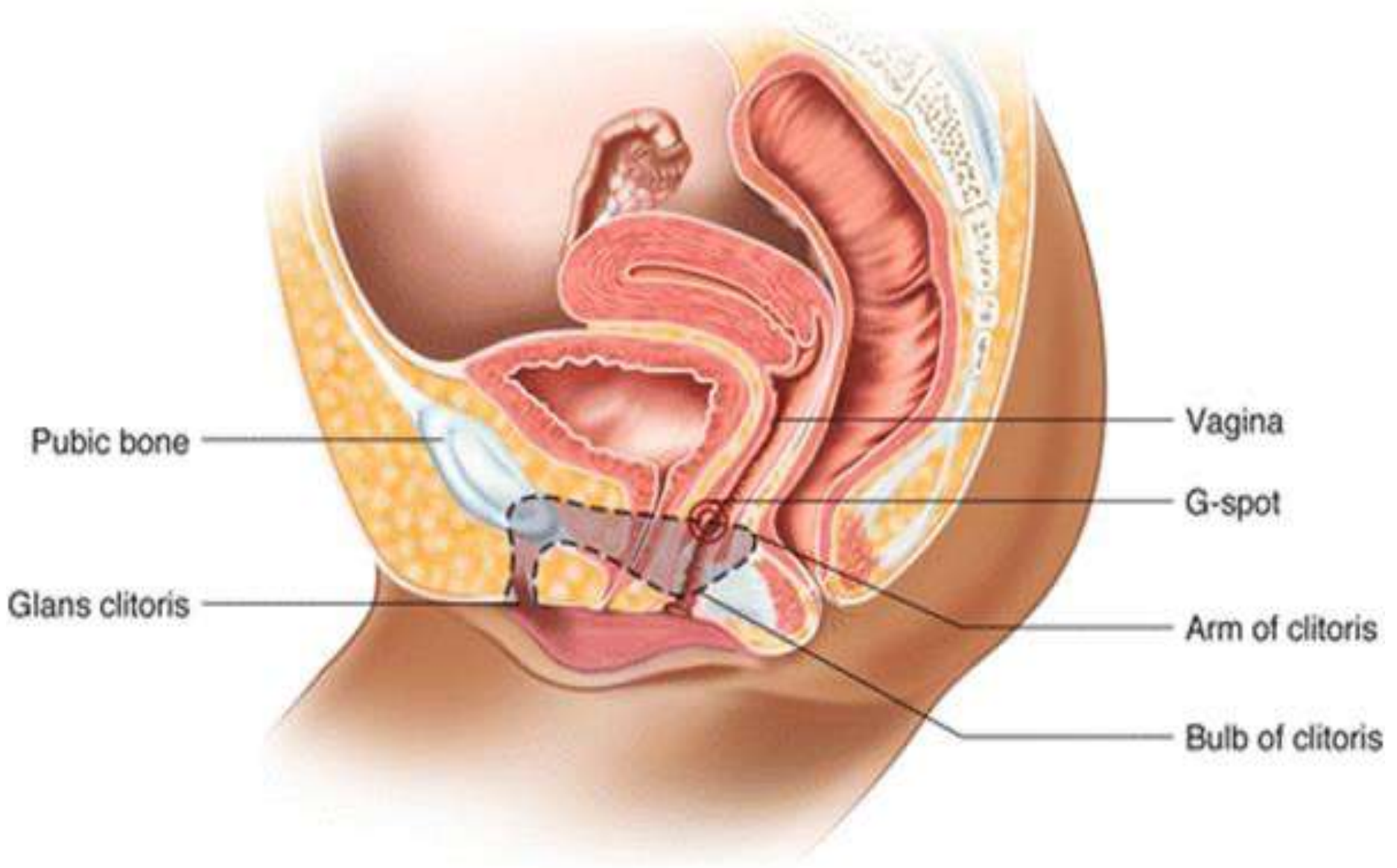






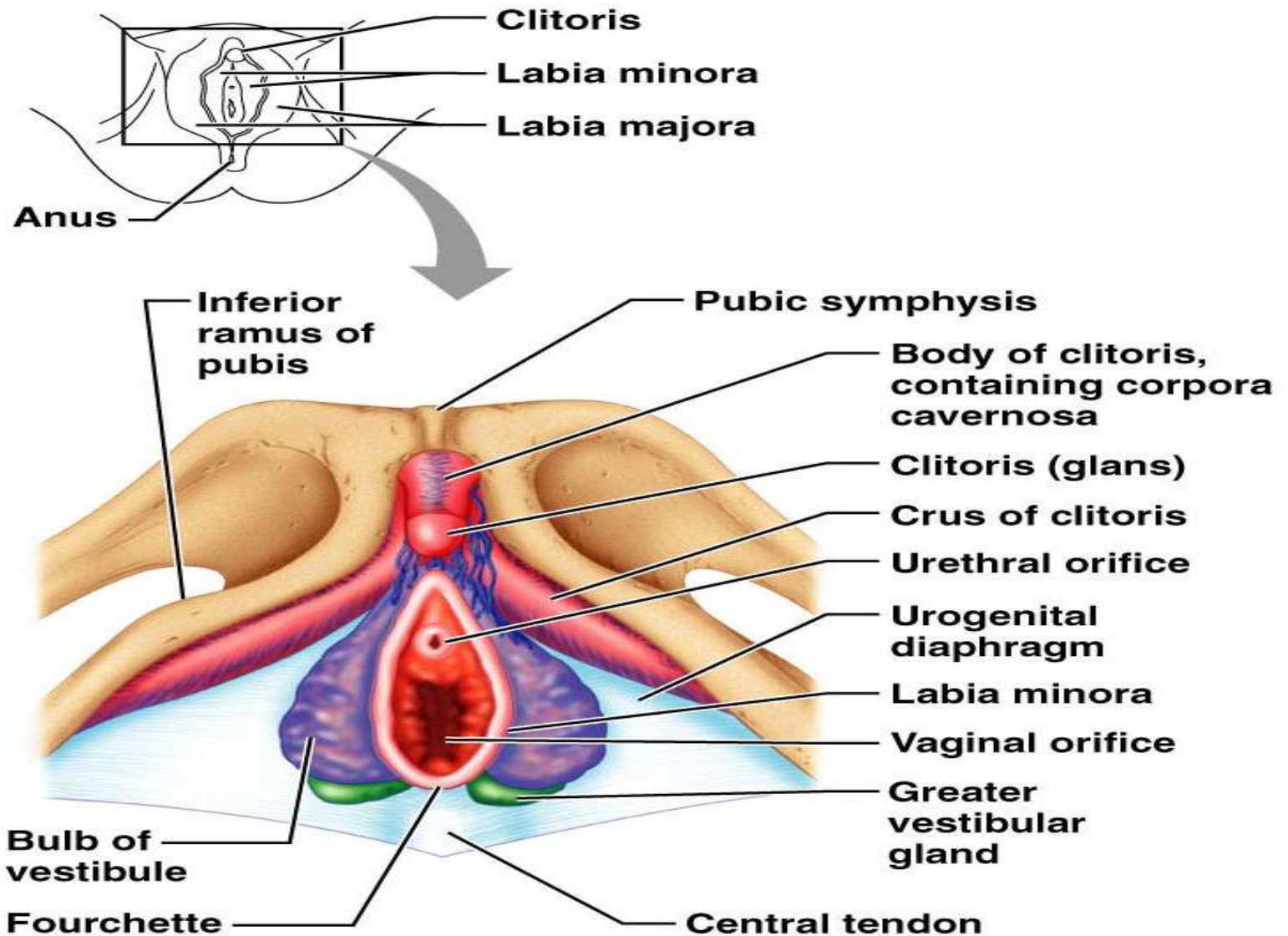


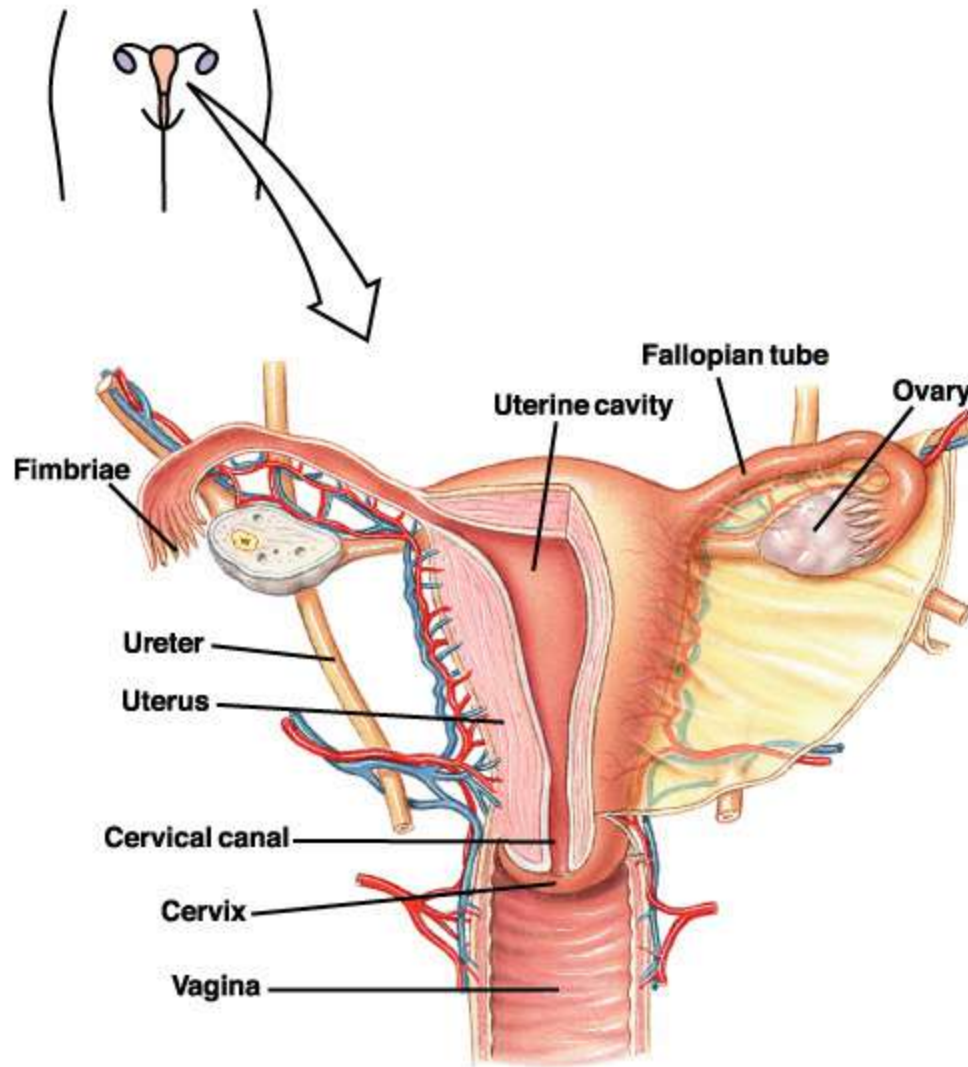


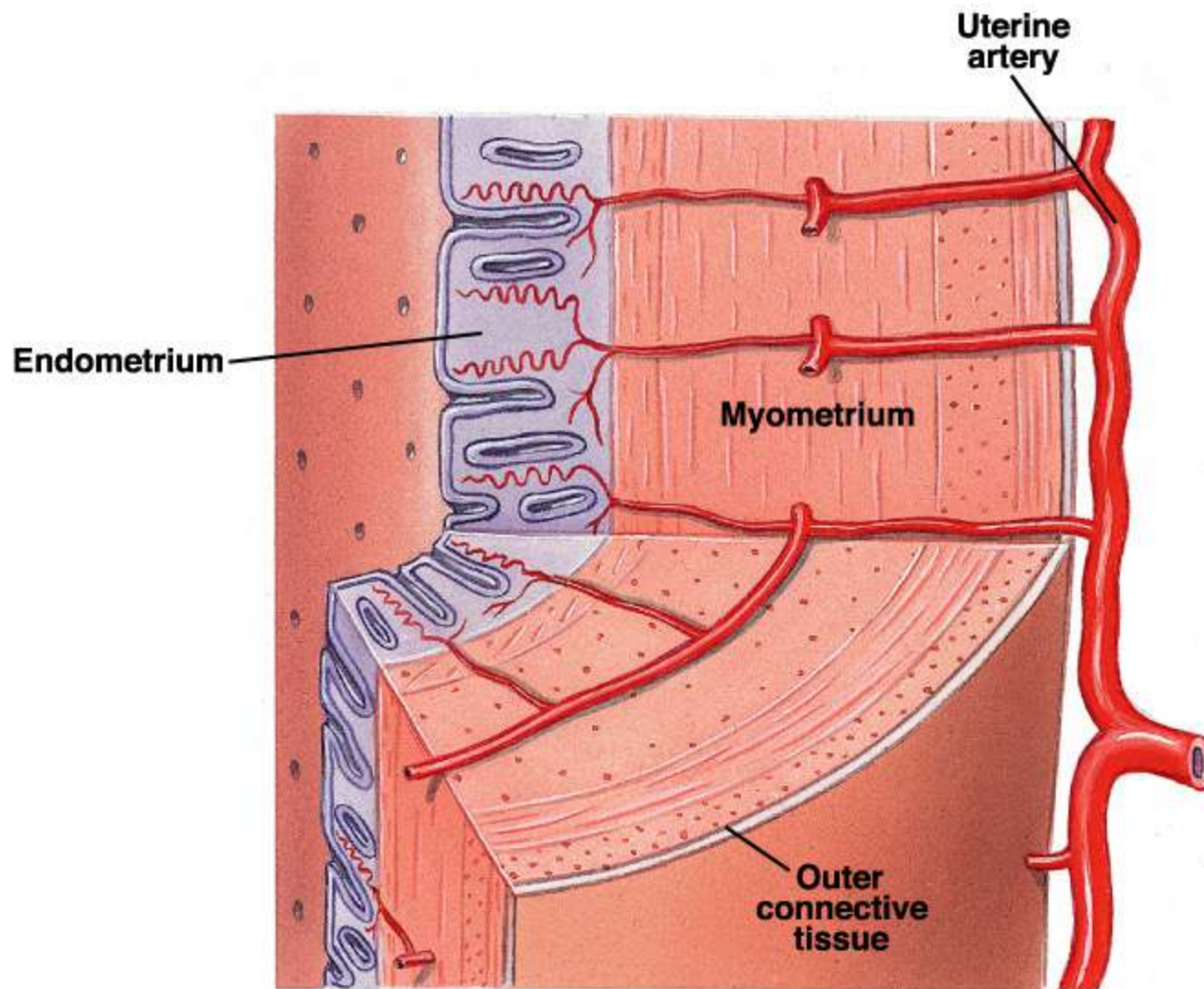




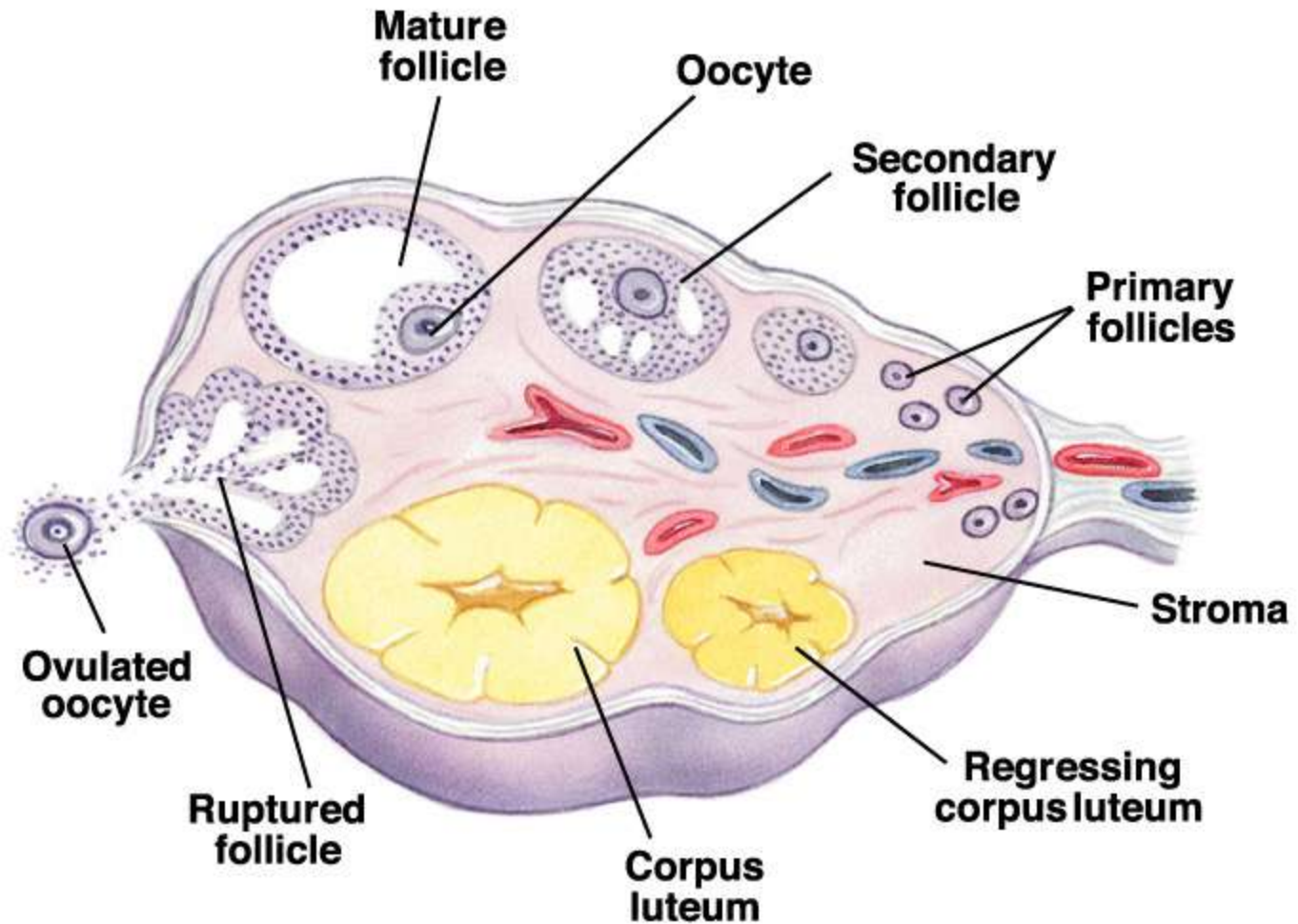
# Female External Genitalia: Deep

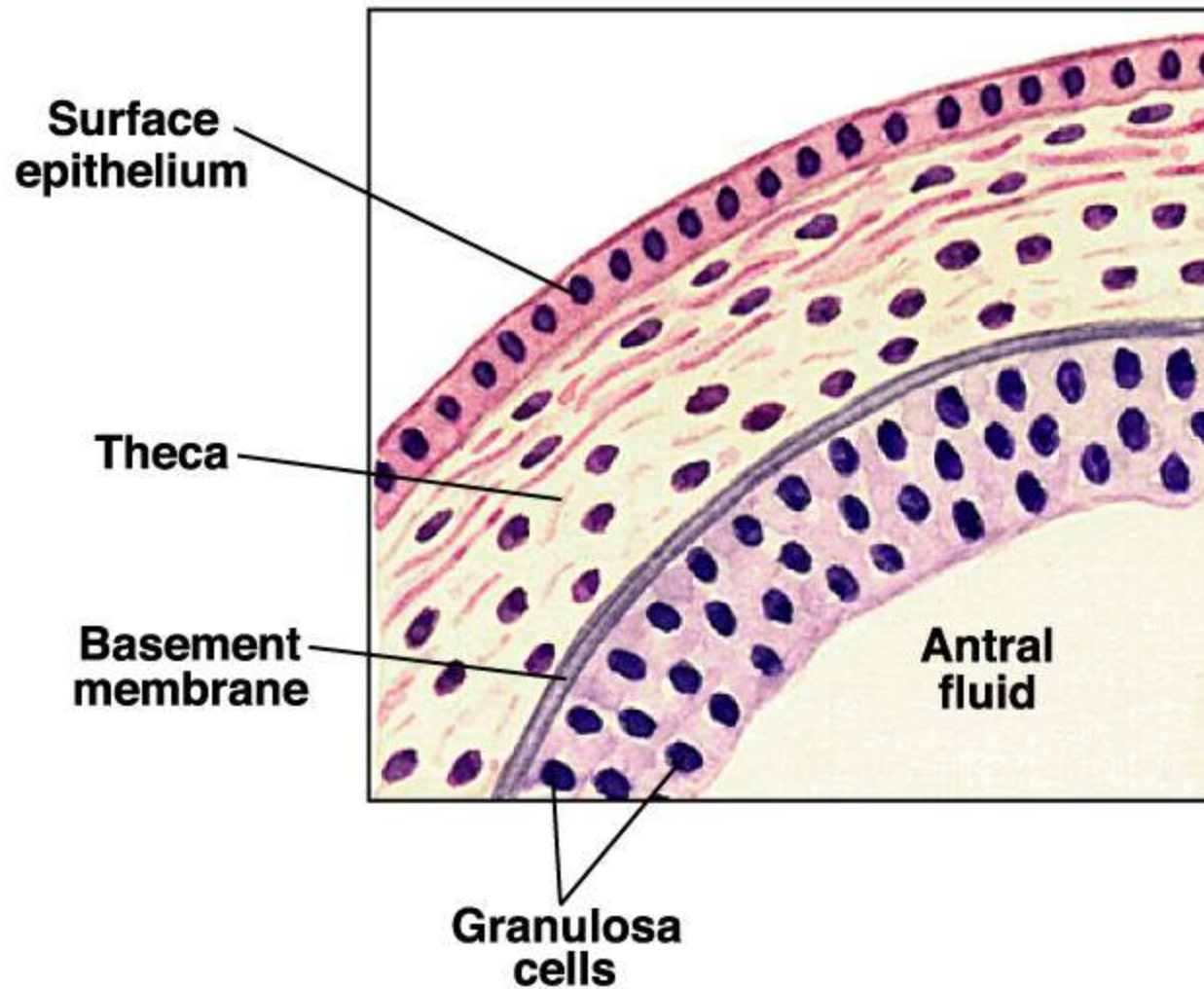




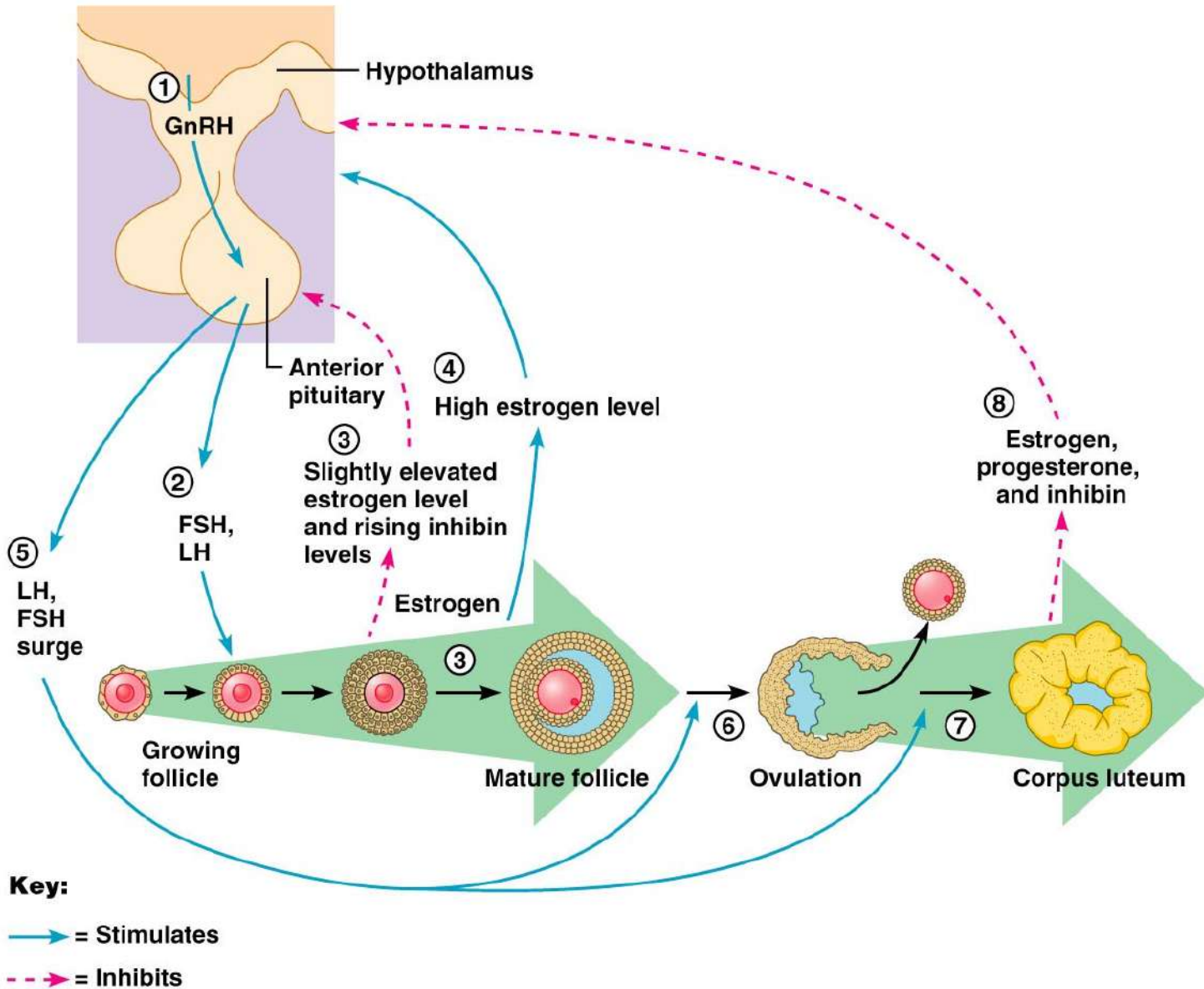


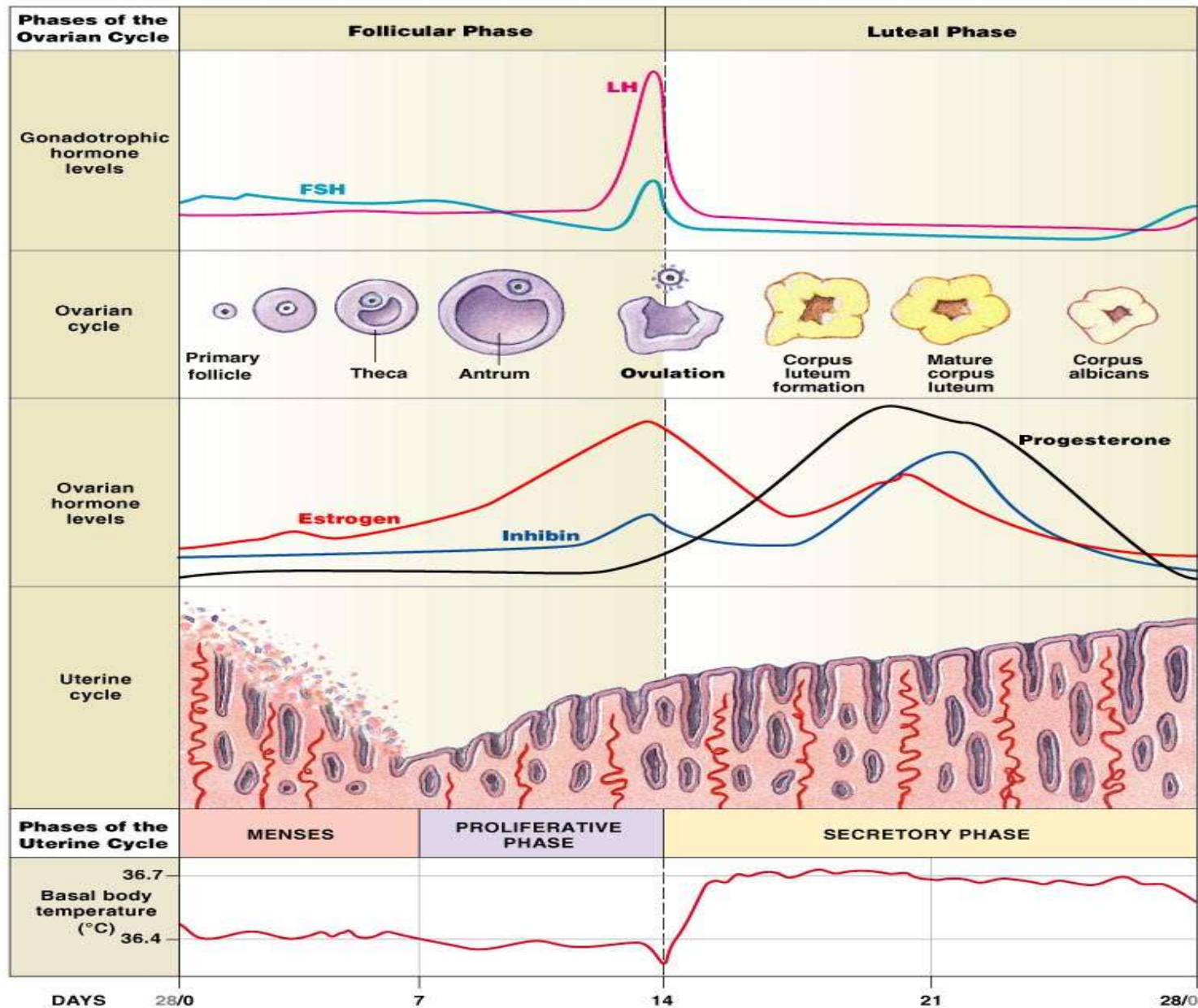






# Feedback Mechanisms in Ovarian Function

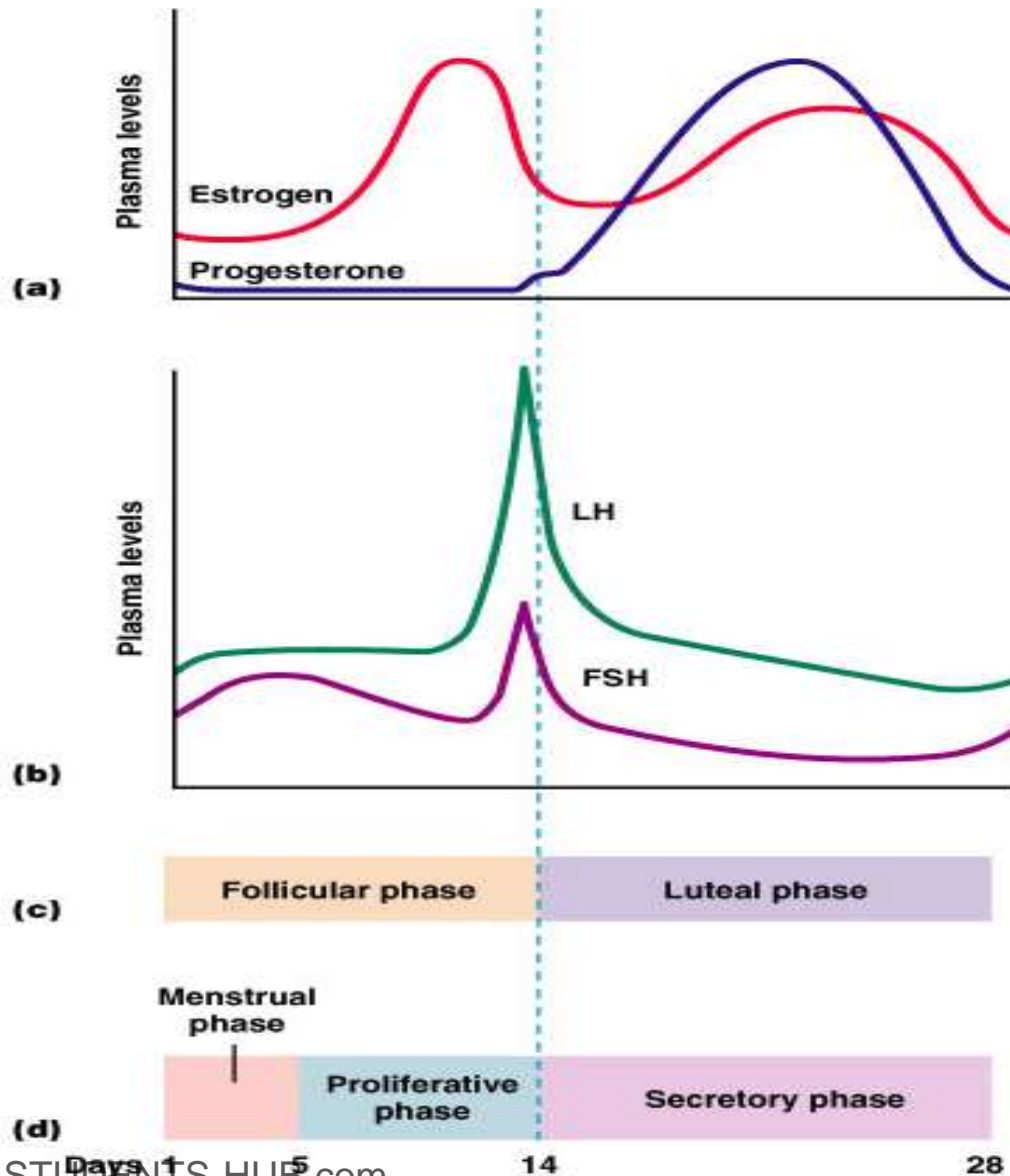




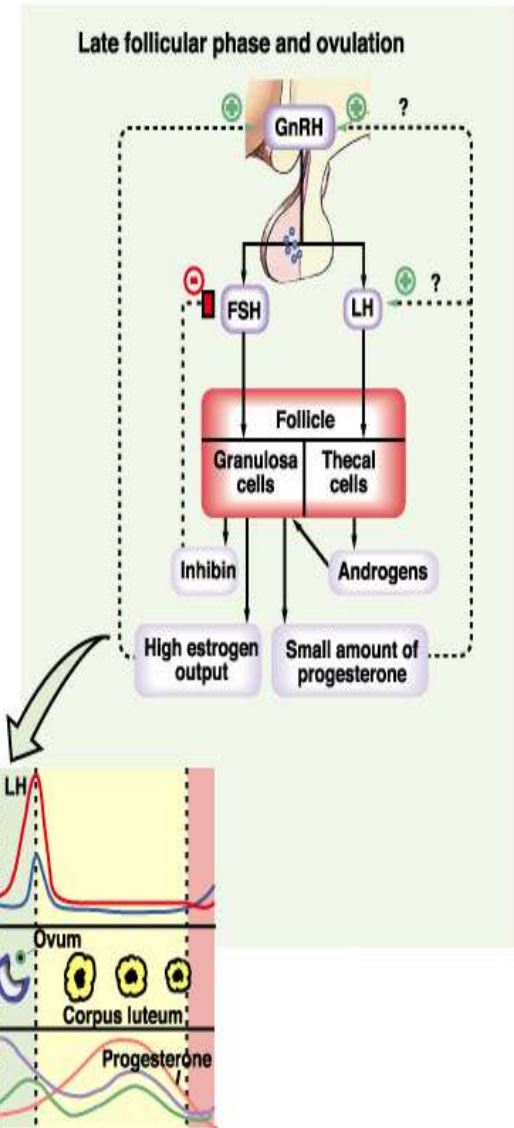
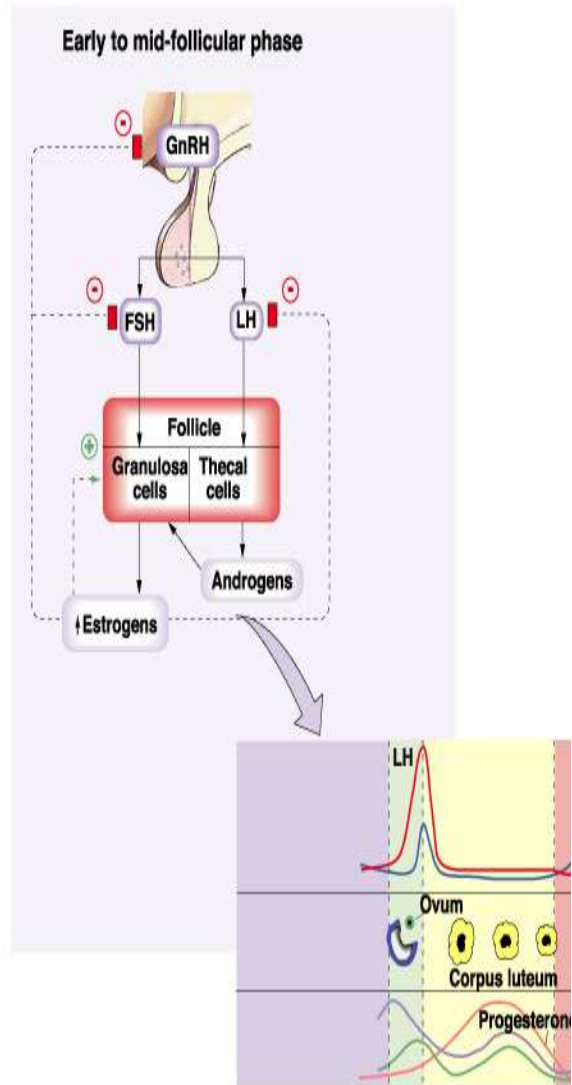
Copyright © 2007 Pearson Education, Inc., publishing as Benjamin Cummings.

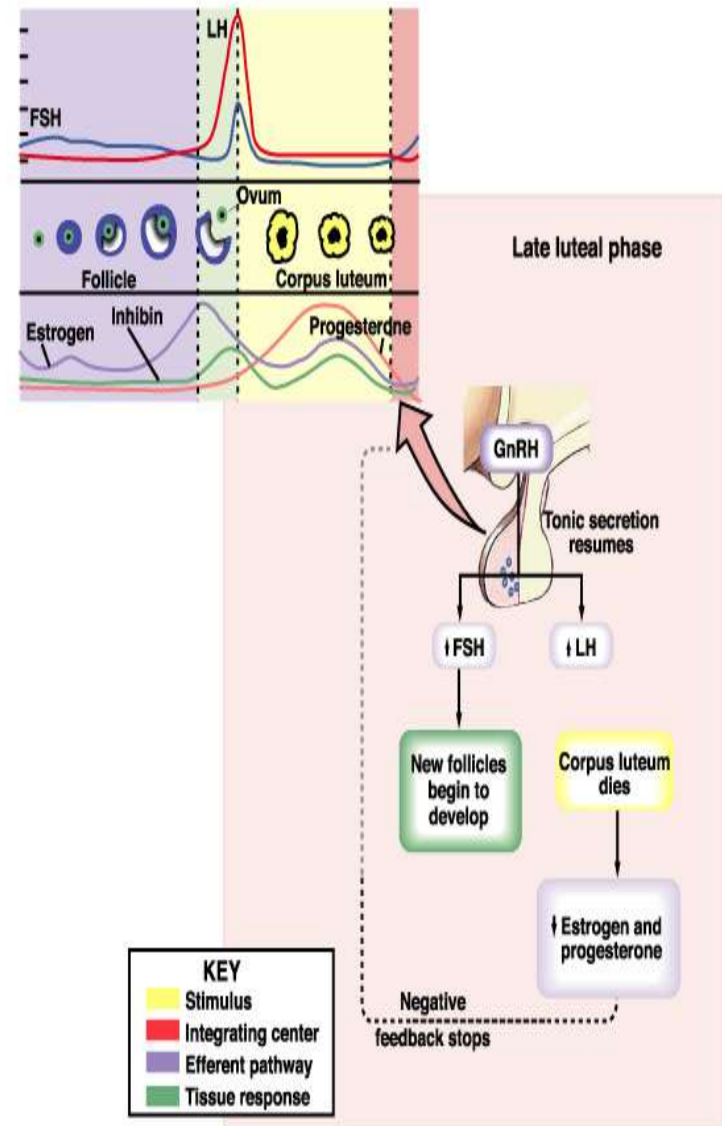
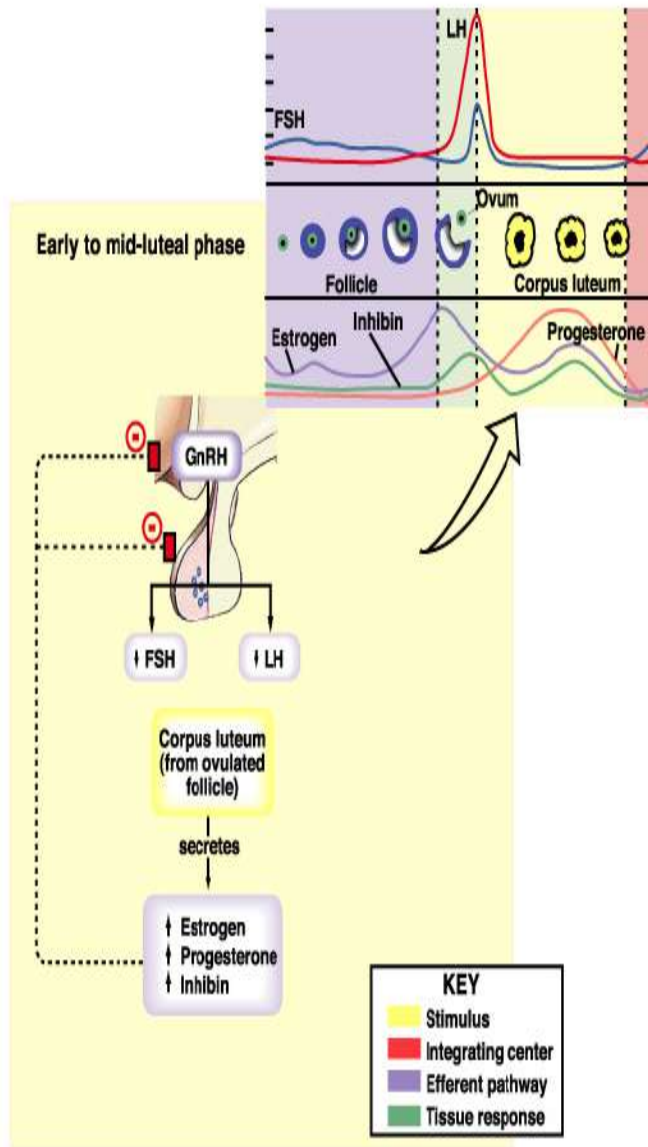


# Hormonal Changes During Menstrual Cycle

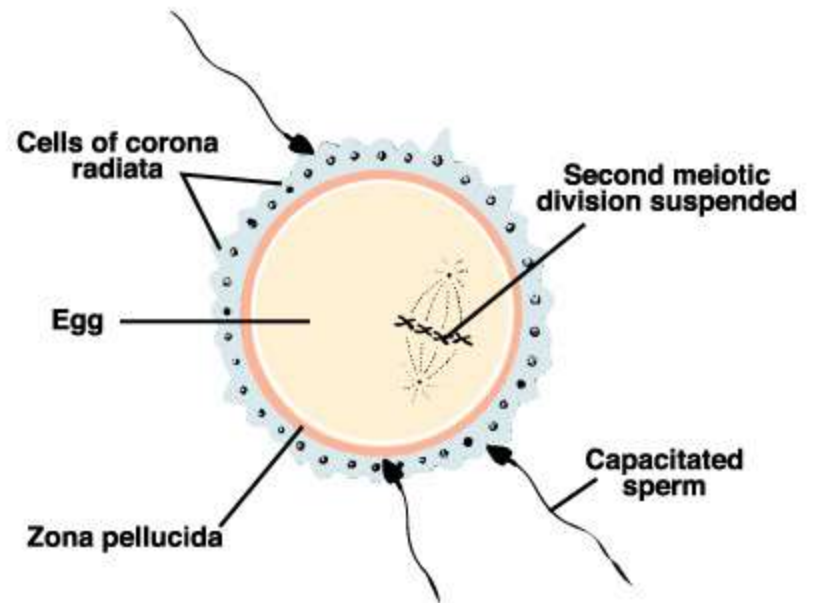
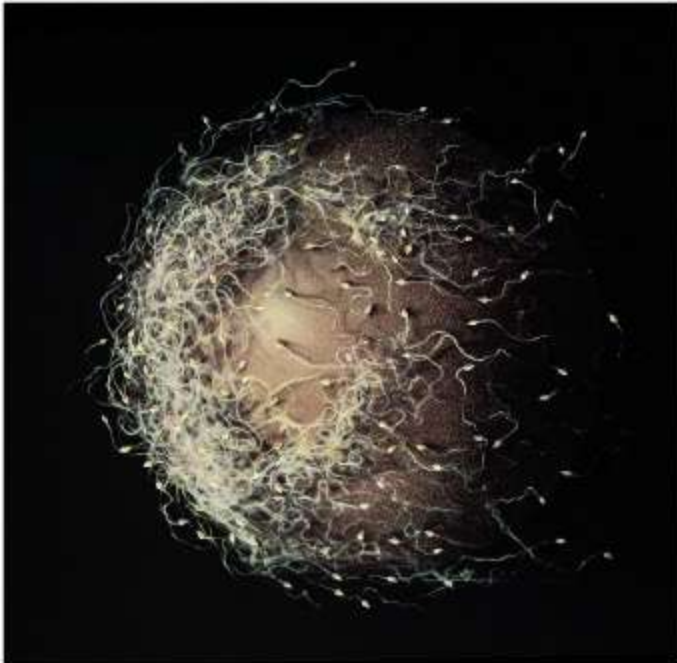

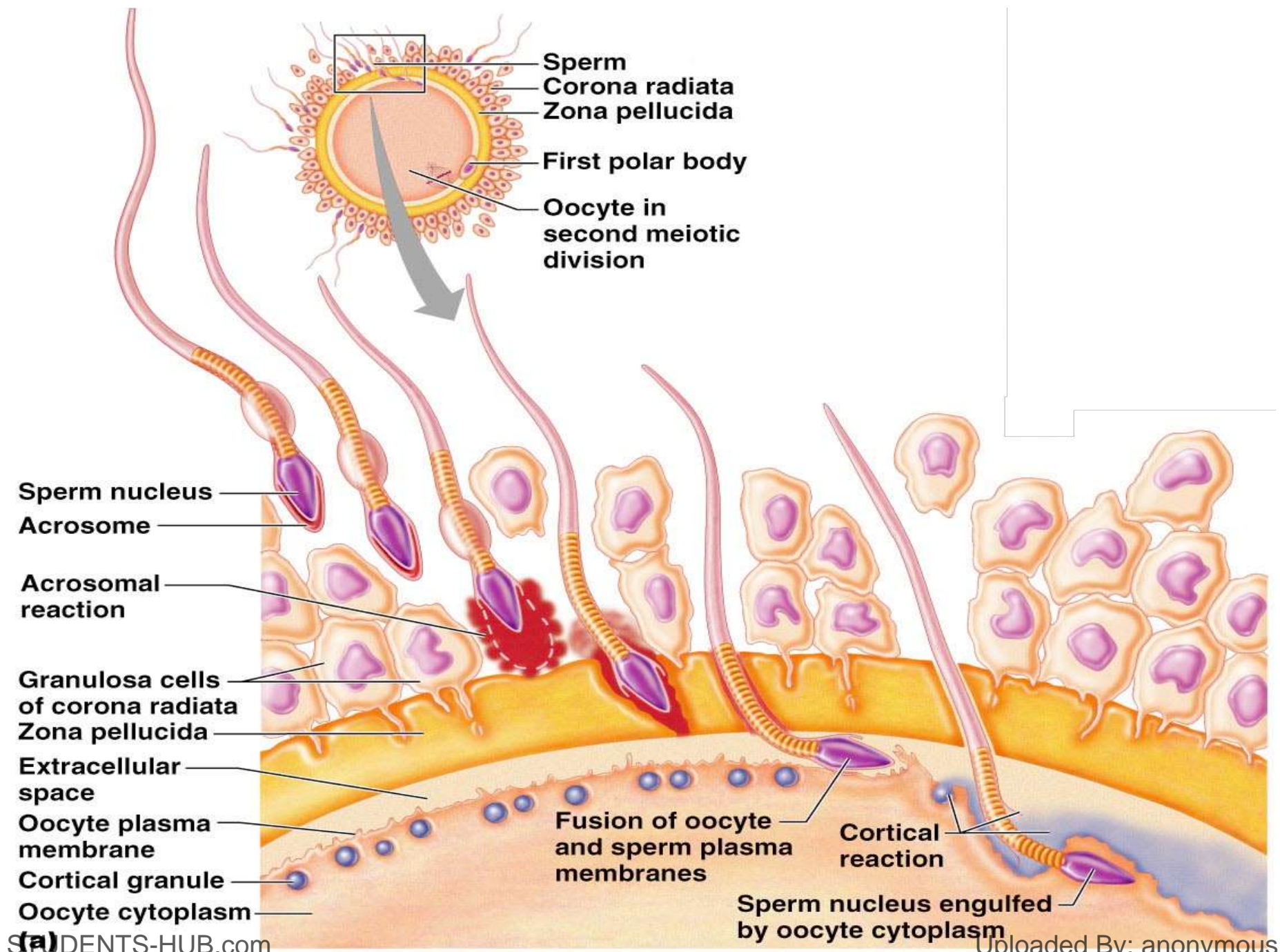
- Estrogen secreted from follicle 1st, then corpus luteum
- Progesterone secreted from corpus luteum
- LH and FSH secreted from anterior pituitary
- Estrogens and progesterone inhibit LH and FSH secretion

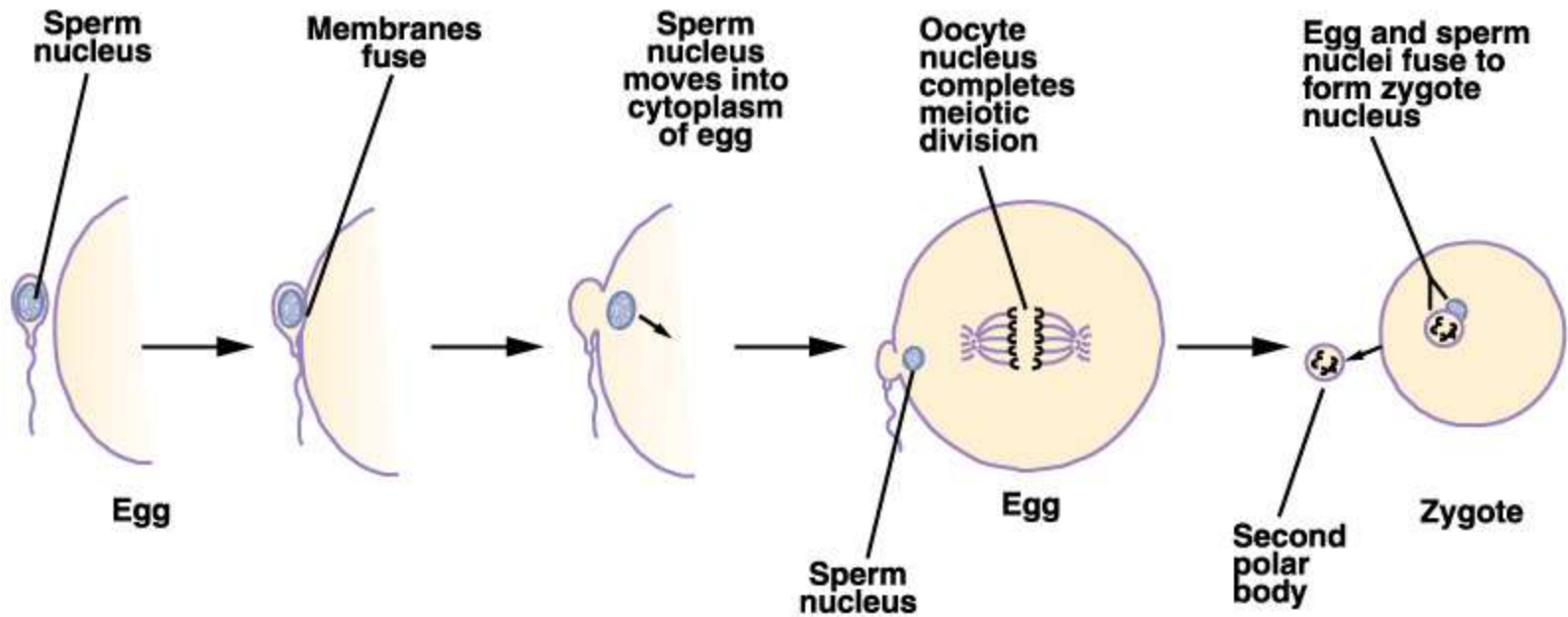






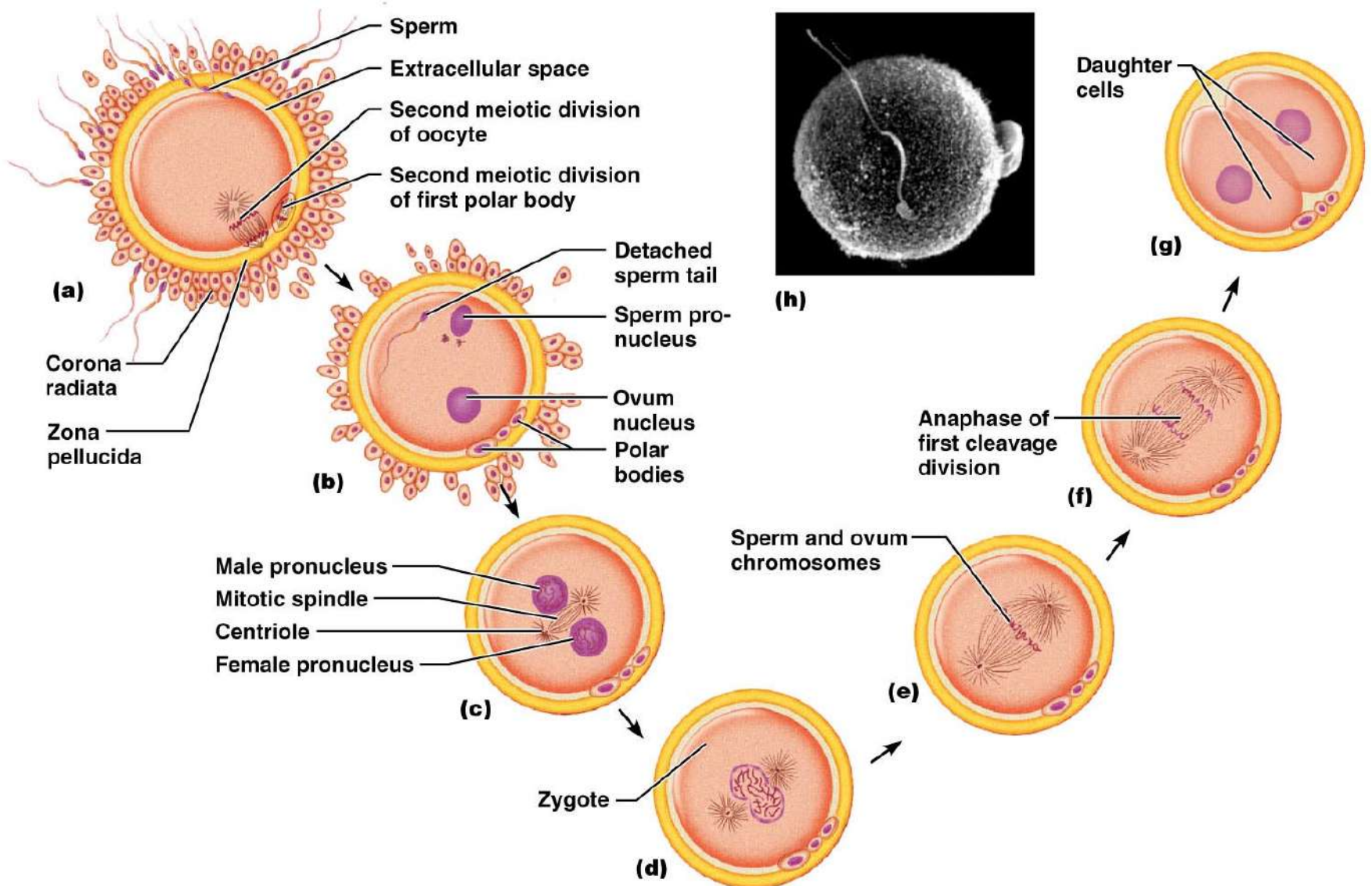




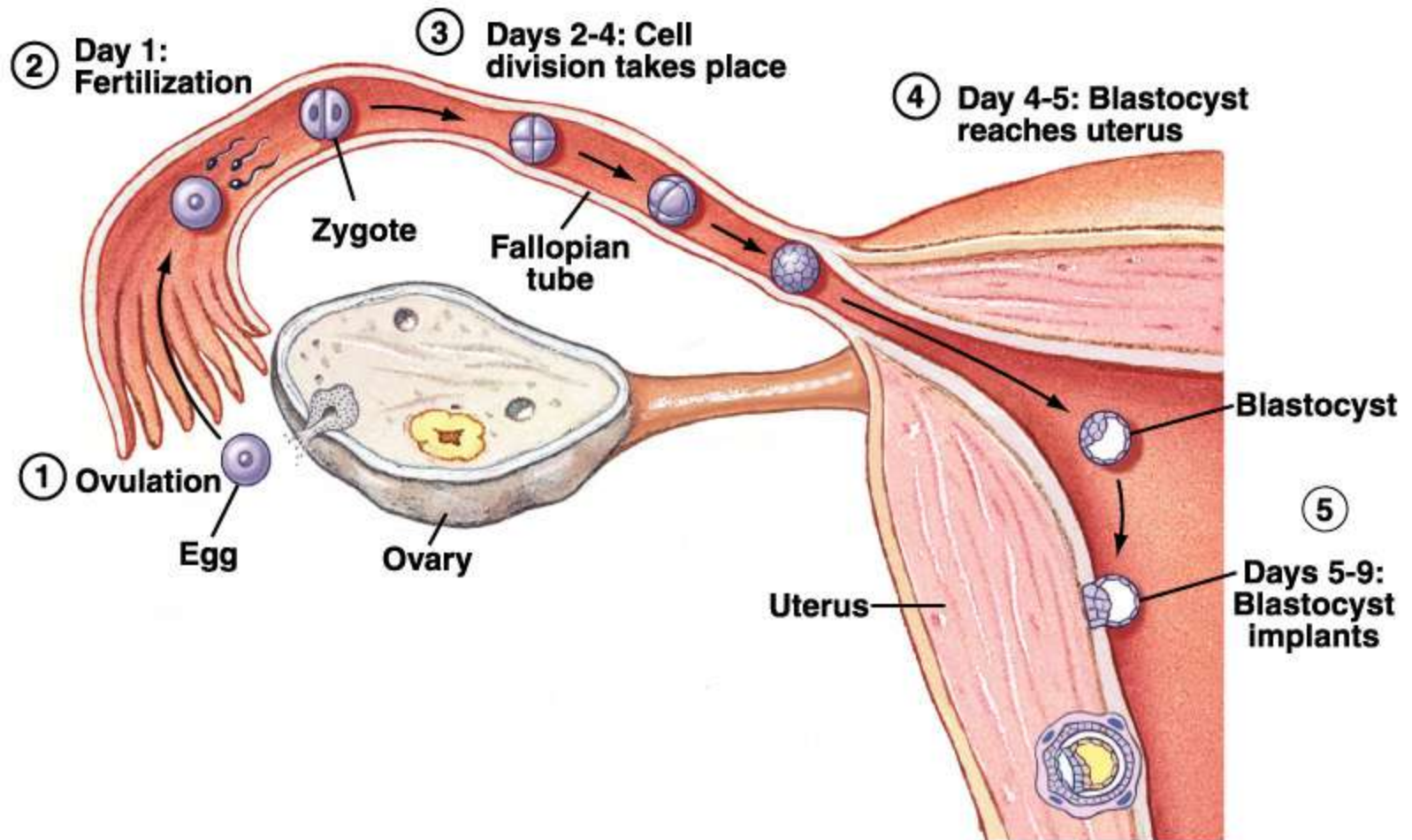




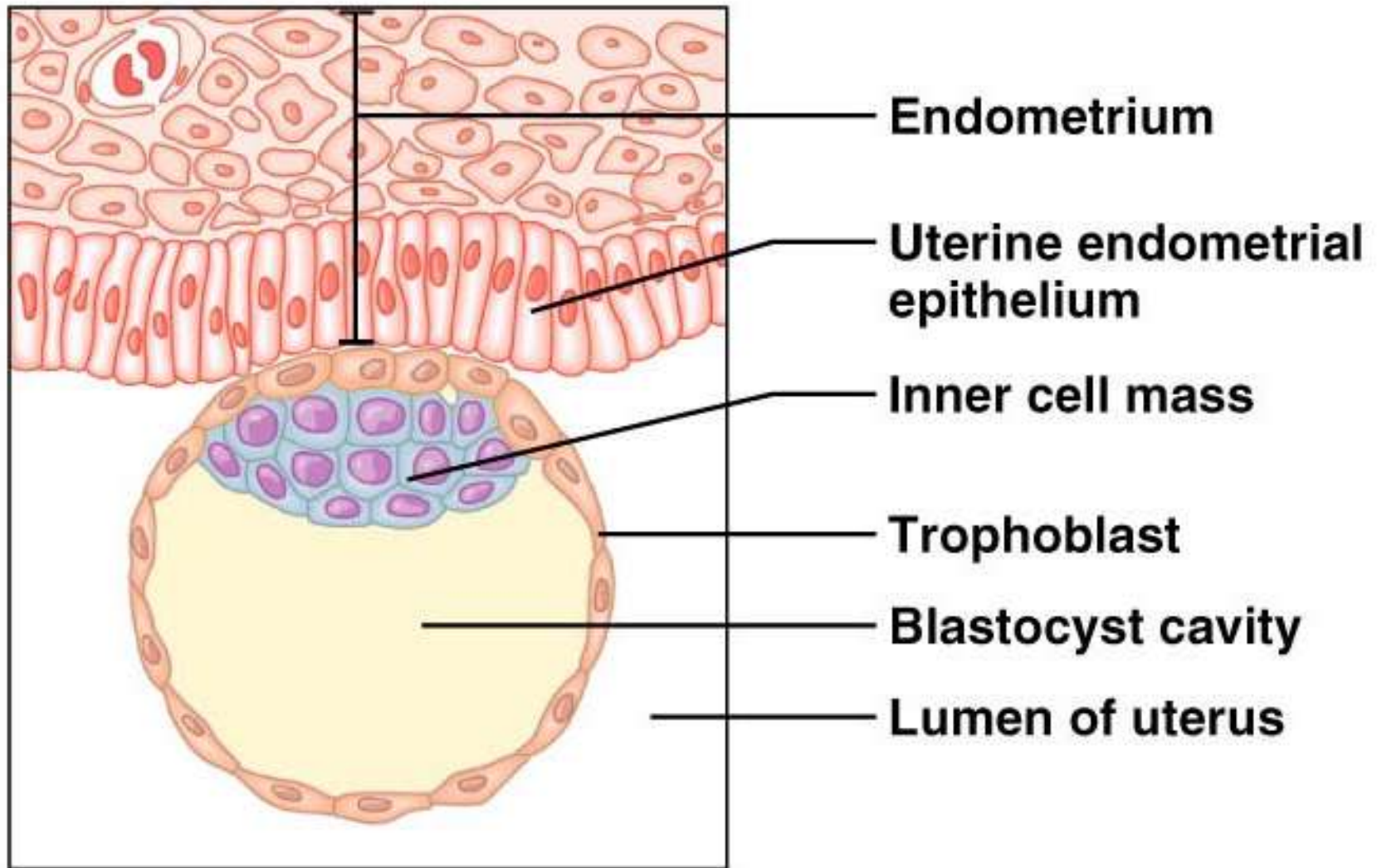
# Events Immediately Following Sperm Penetration





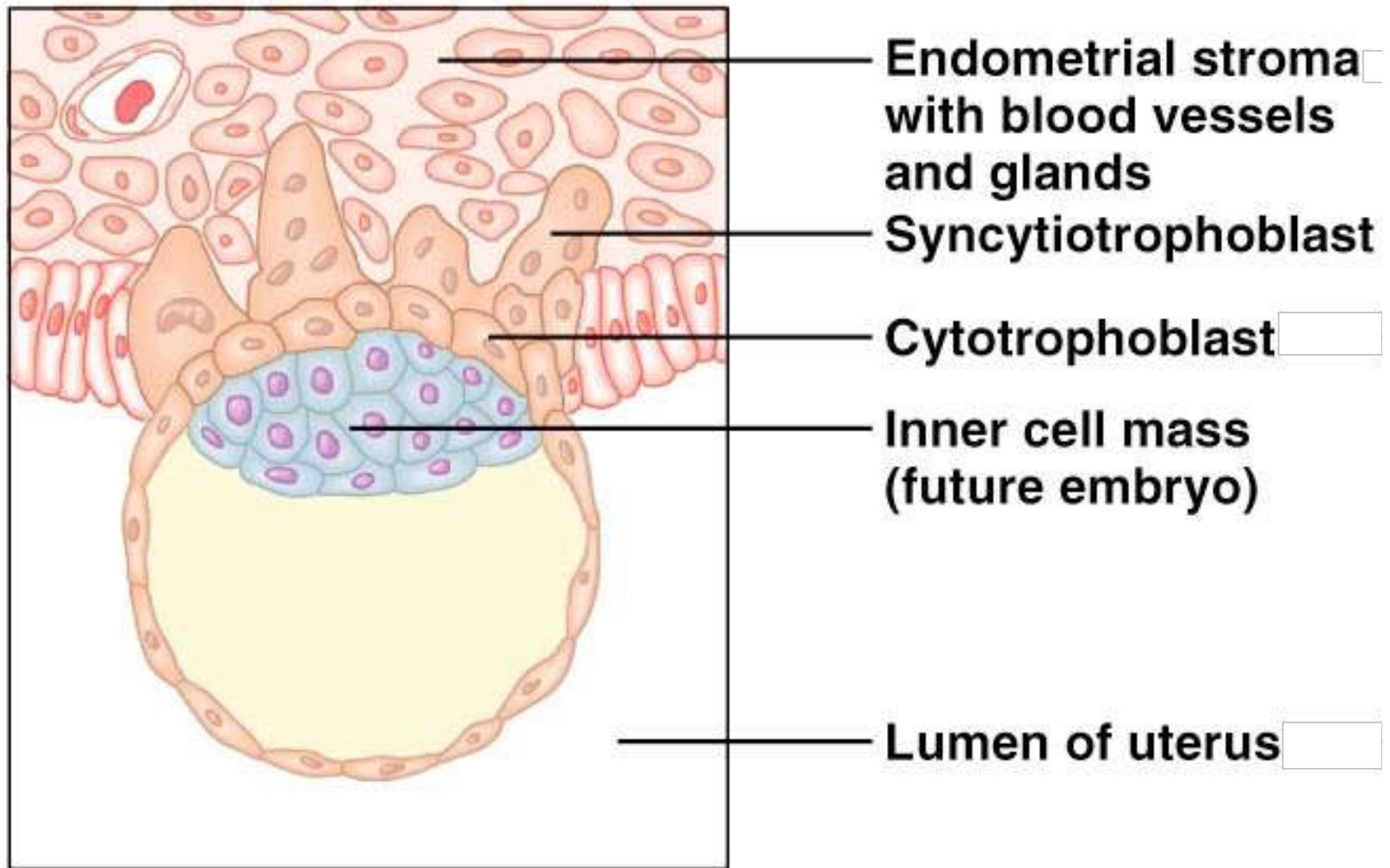


# Implantation of the Blastocyst



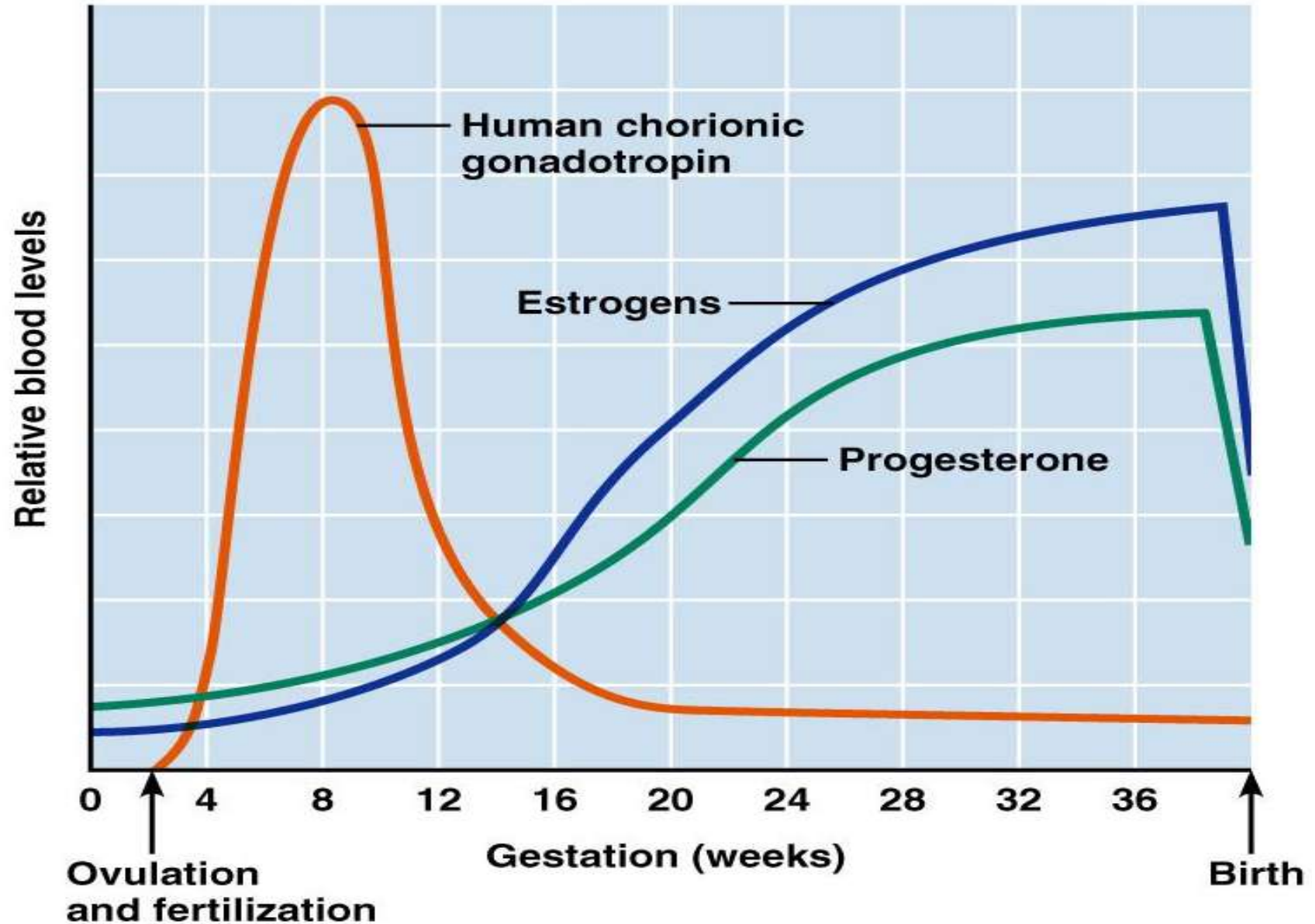
**(a)**

# Implantation of the Blastocyst

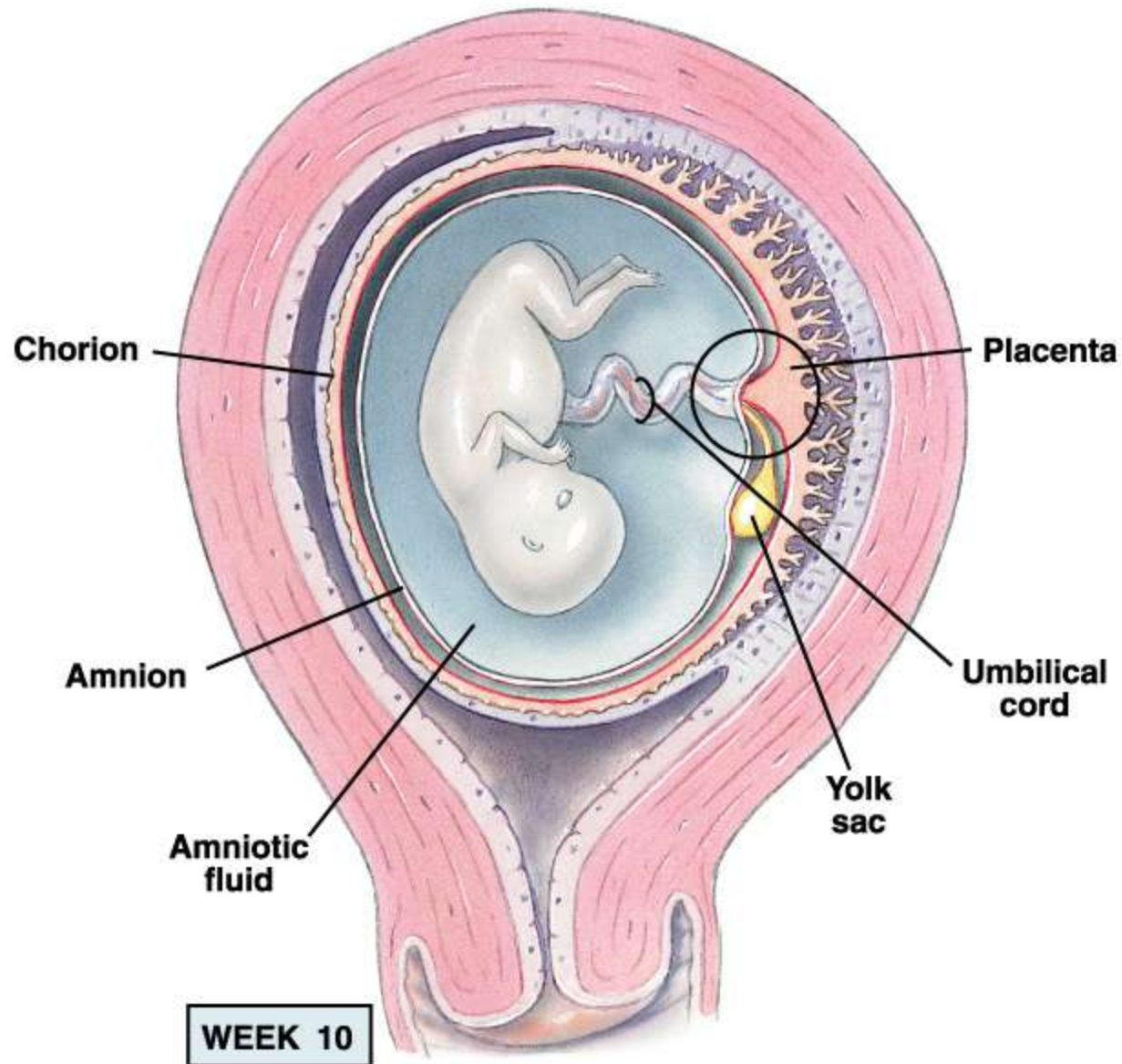


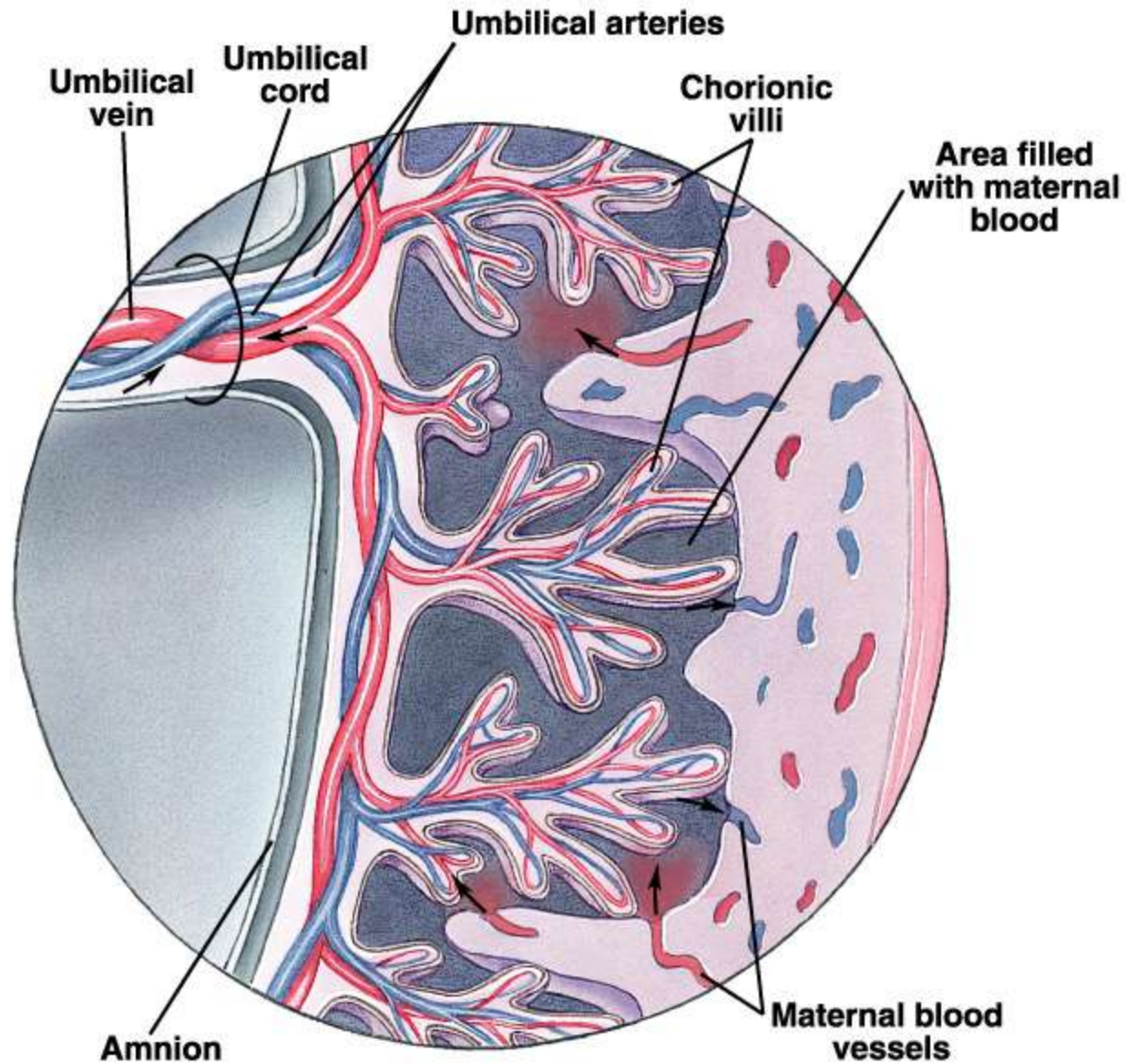
**(b)**

# Hormonal Changes During Pregnancy



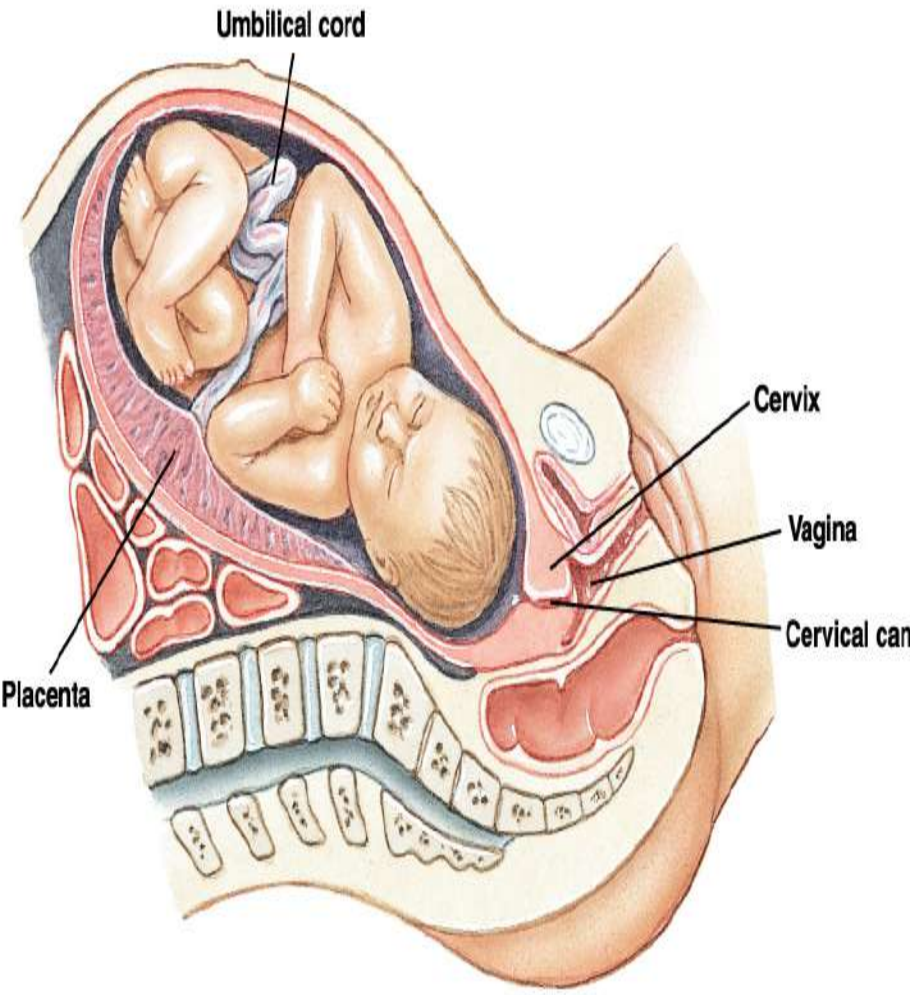




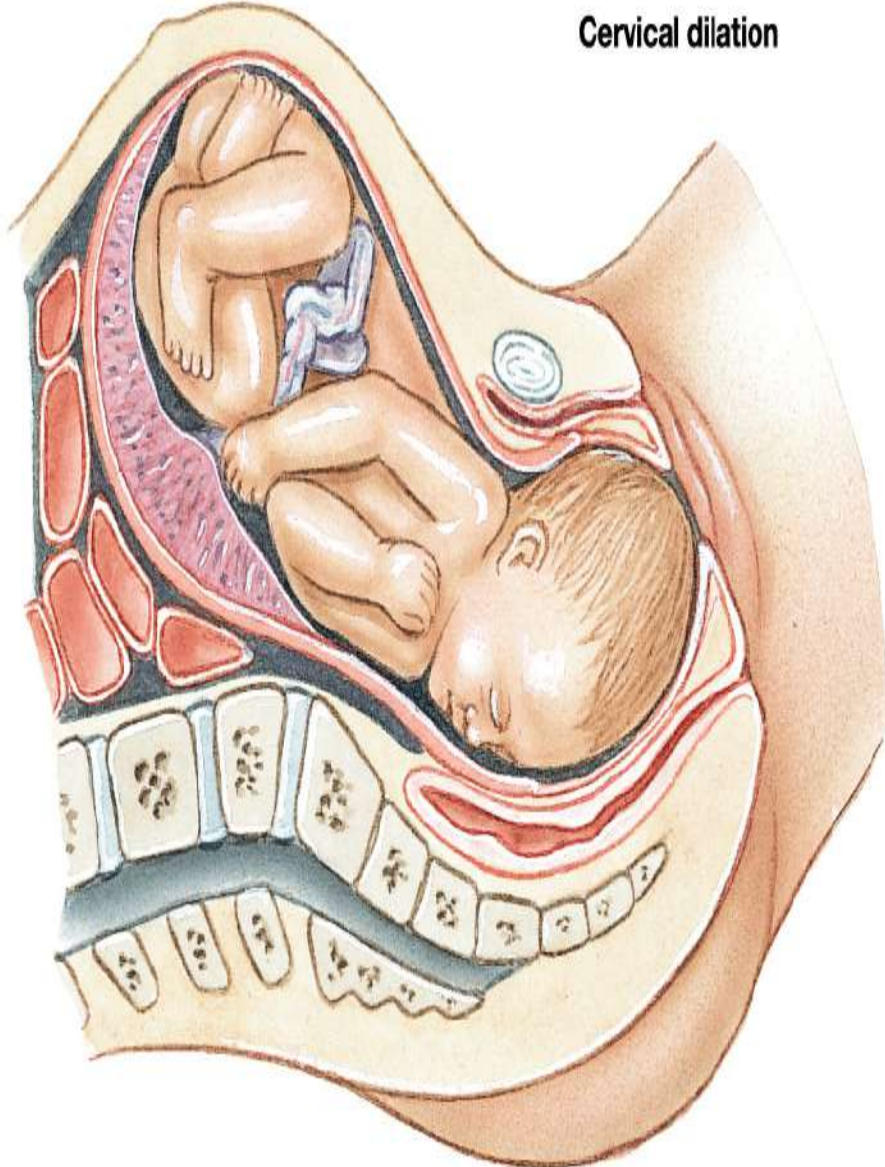




Fully developed fetus

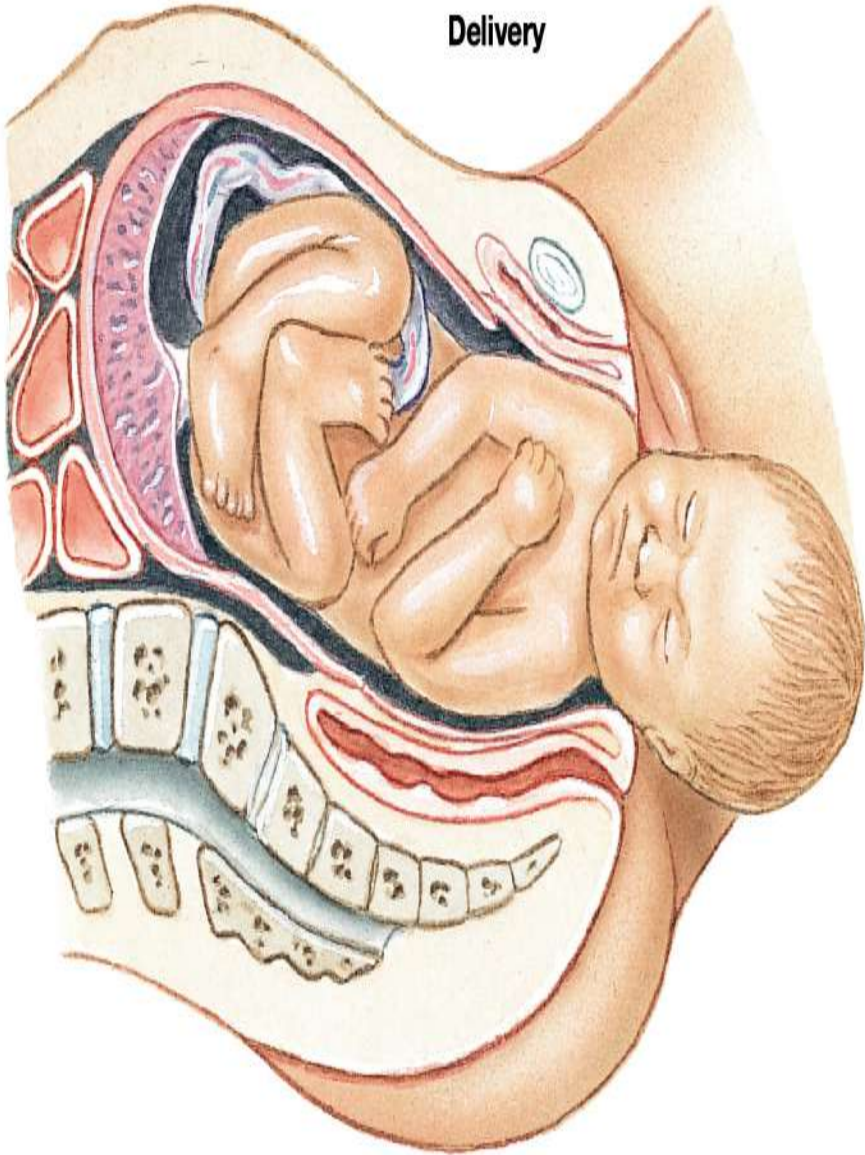


Cervical dilation

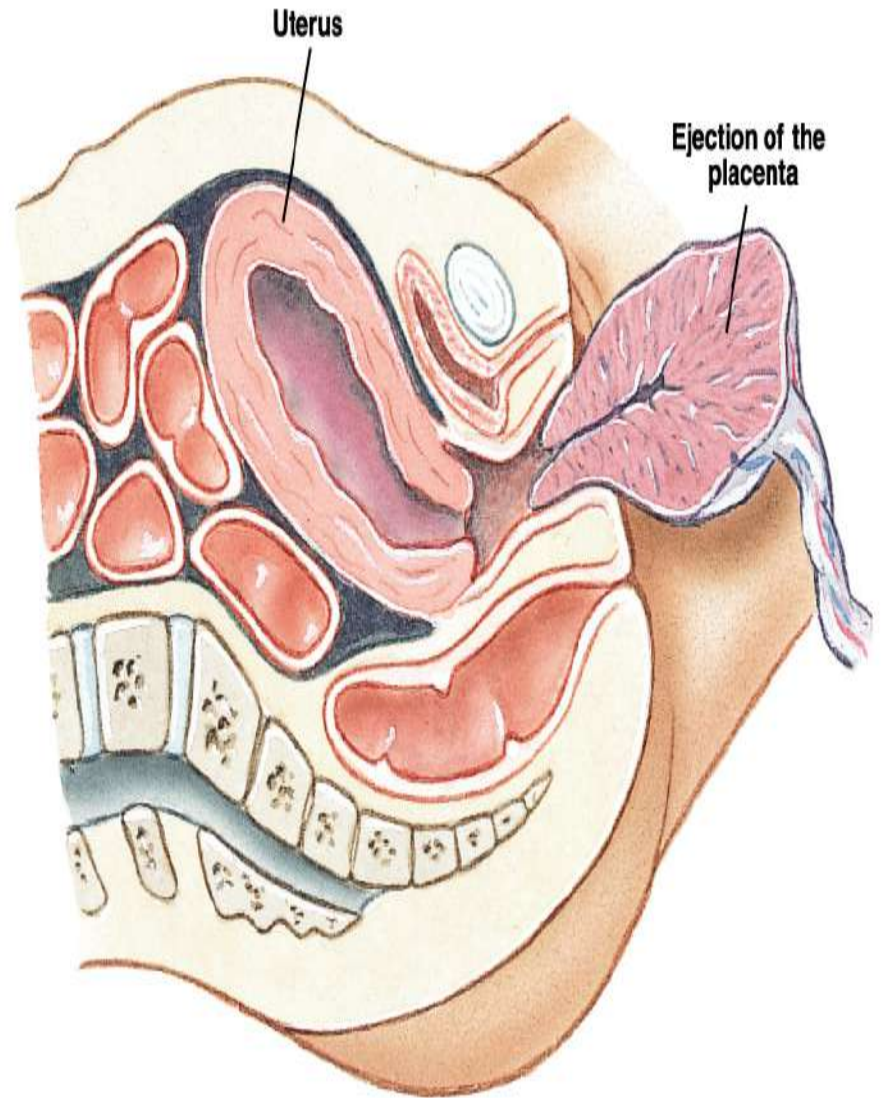




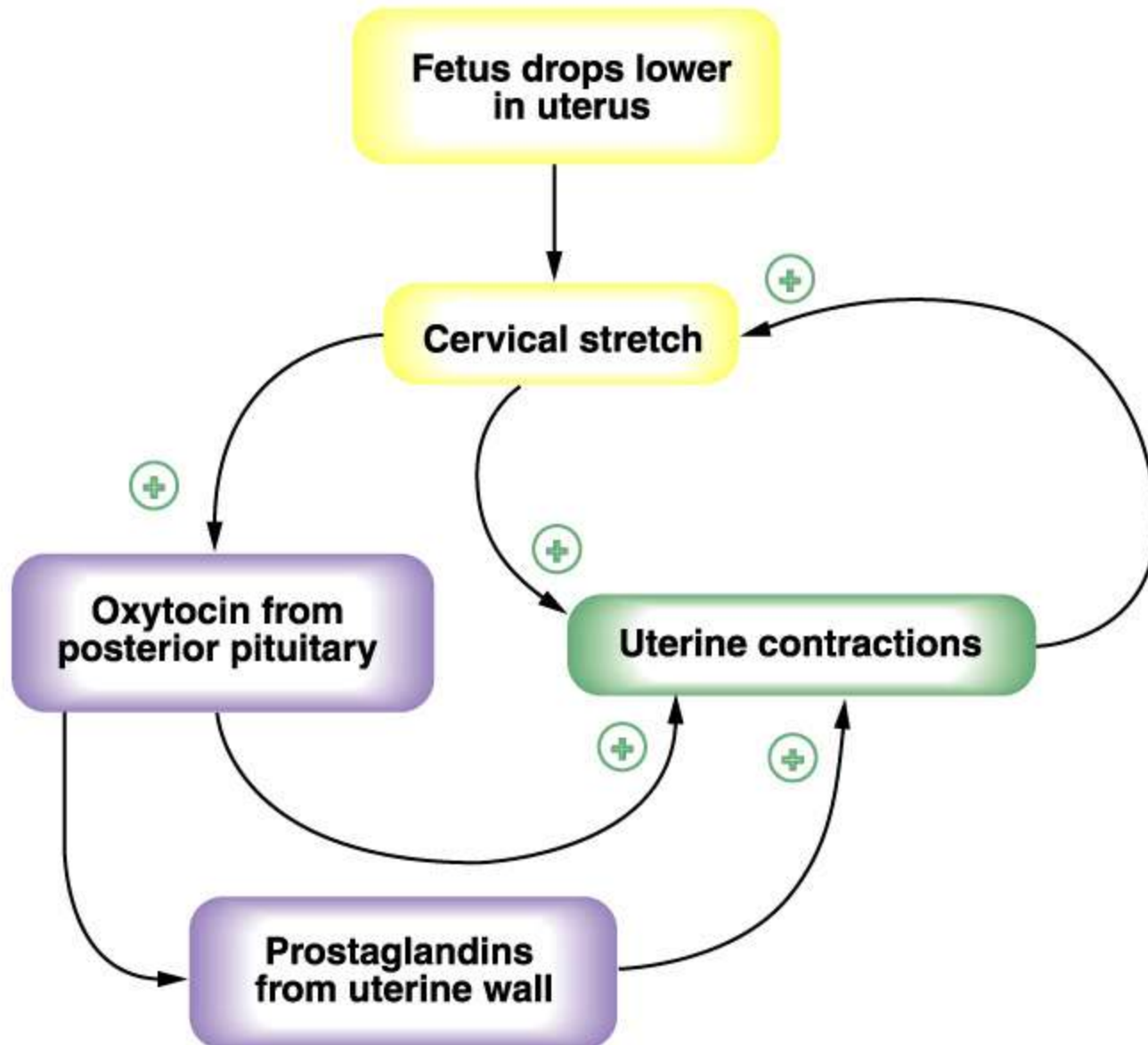
**Delivery**

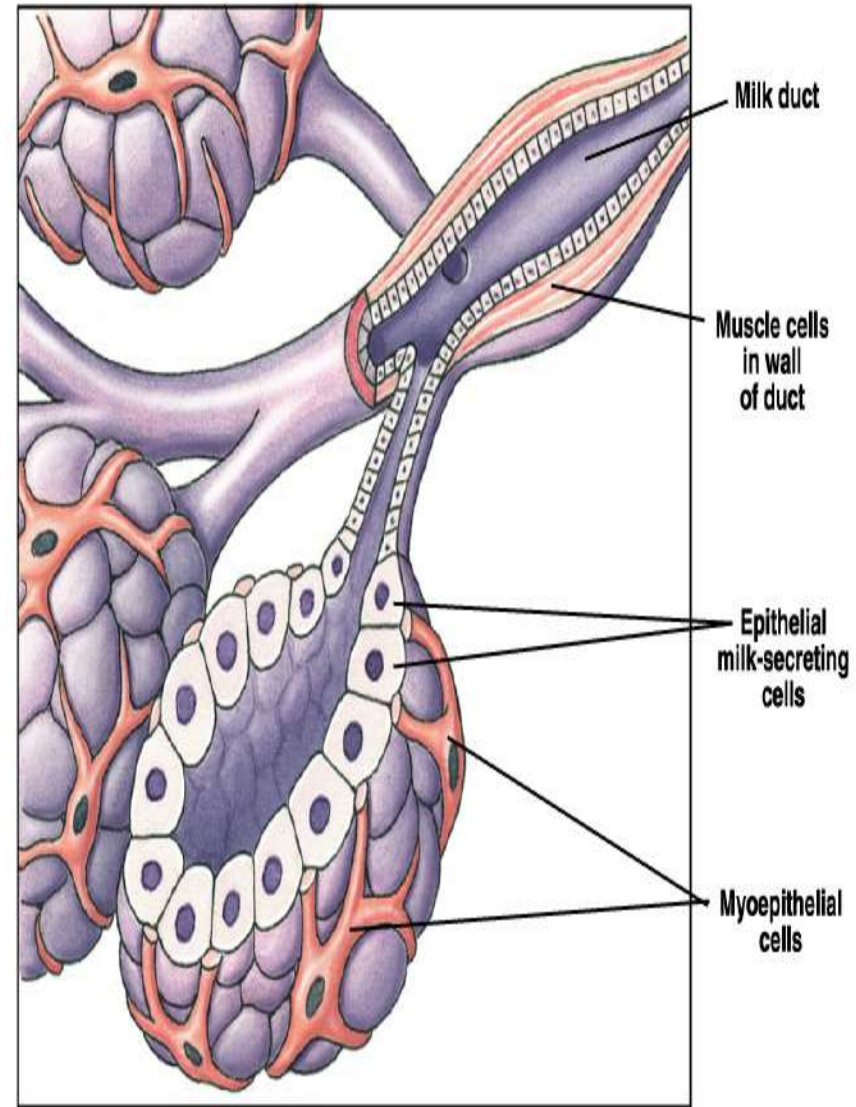
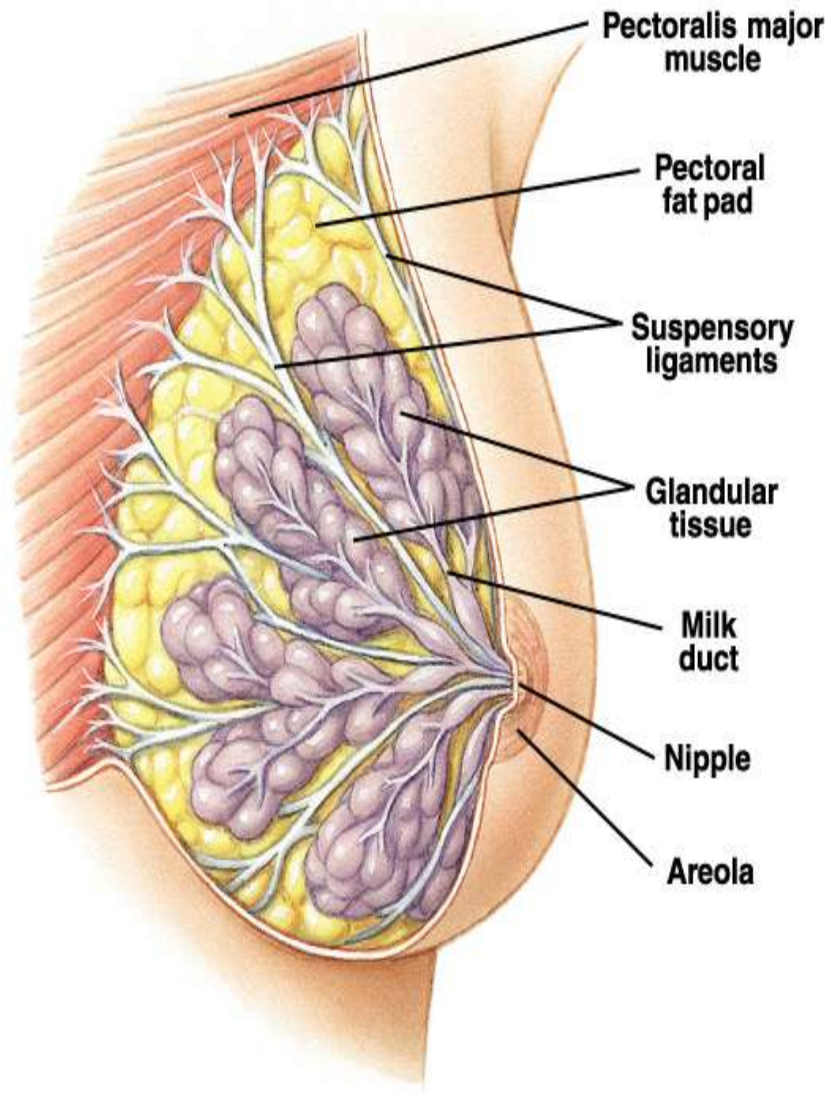


**Expulsion of the placenta**



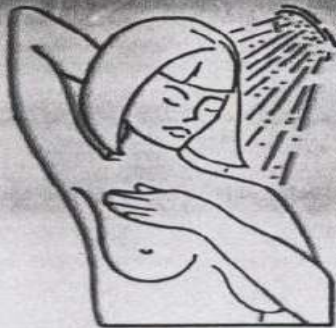







### 1 In the bath or shower:



Examine your breasts during bath or shower. With flat fingers move gently over every part of each breast. Check for

**lumps, hard knots, or thickenings.**

### 2 Before a mirror:

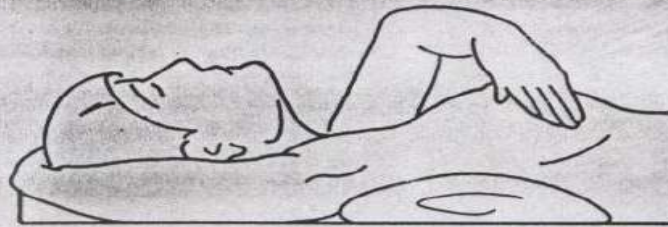
Inspect your breasts with arms at your sides and then with your arms raised overhead. Look for any changes in each breast: a swelling, dimpling of skin or changes in the nipple.



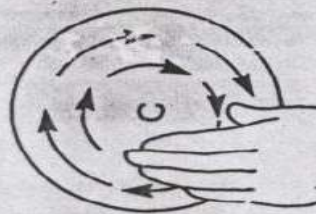
Then, rest palms on hips and press down firmly to flex your chest muscles. Regular inspection shows what is

**normal for you and will give you confidence in your examination.**

### 3 Lying down:



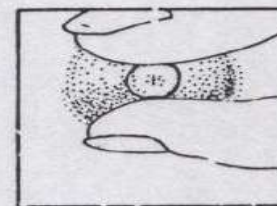
To examine your right breast, put a pillow or folded towel under your right shoulder. Place right hand behind your head - this distributes breast tissue more evenly on the chest. With left hand, fingers flat,

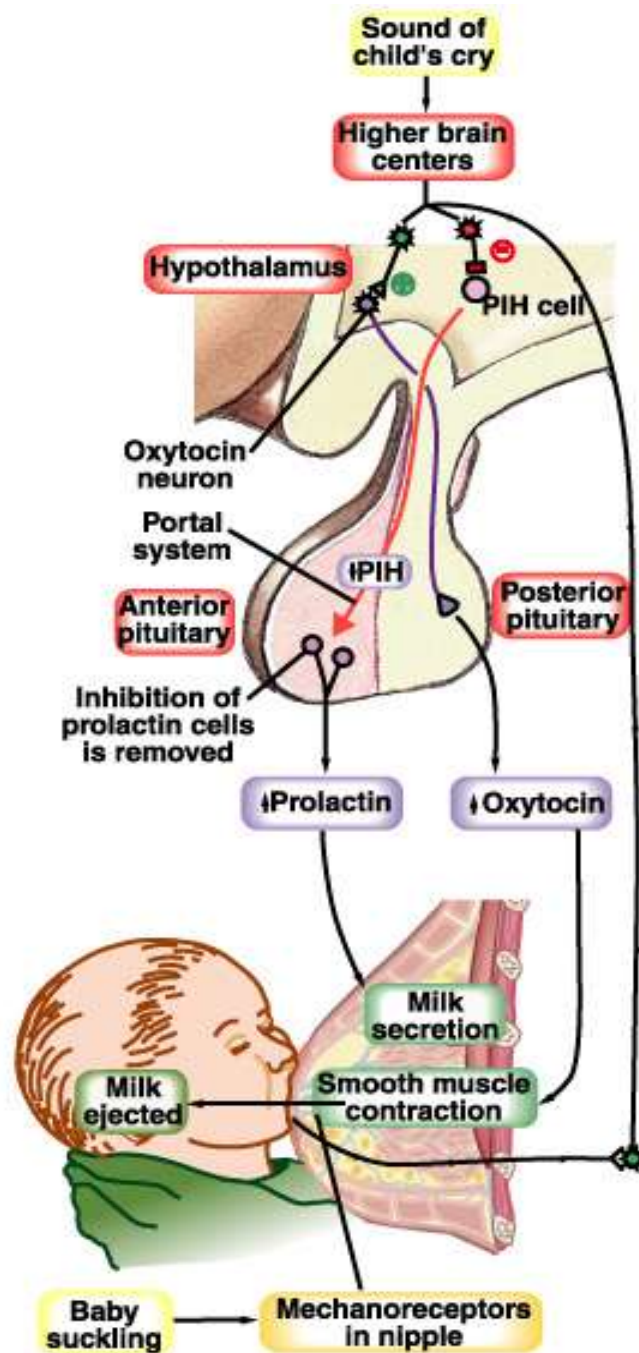


press gently in small circular motions around an imaginary clock face. A ridge of firm tissue in the lower curve of

each breast is normal. Then move in an inch, toward the nipple, keep circling to examine every part of your breast, including nipple. Now slowly repeat procedure on your left breast.

Squeeze the nipple of each breast gently between thumb and index finger. Any discharge, clear or bloody, should be reported to your doctor immediately.



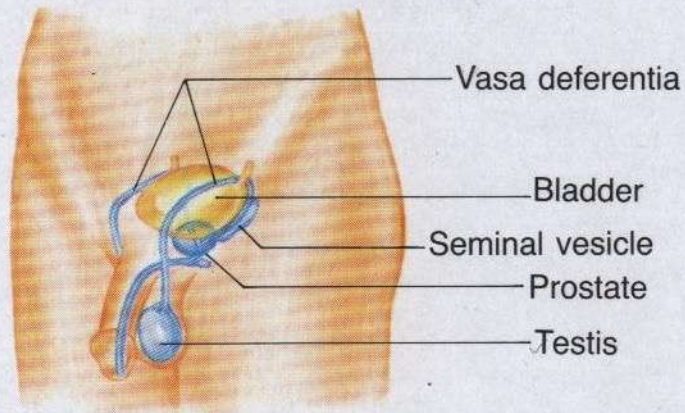




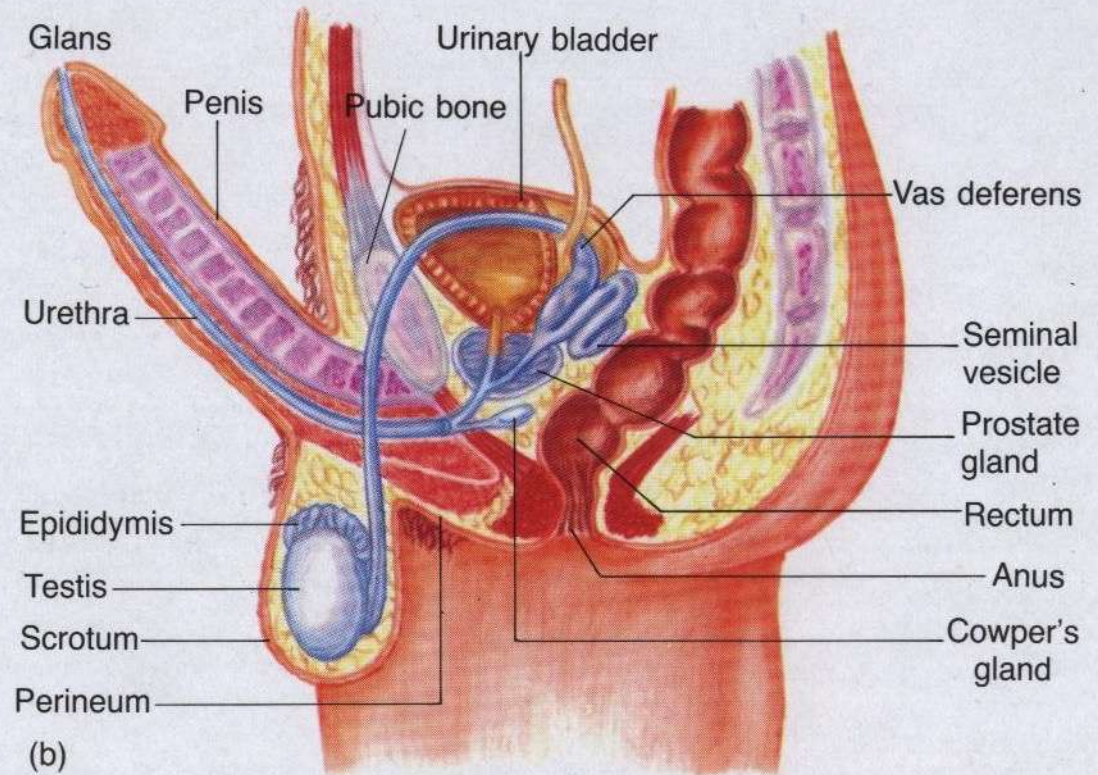
URINARY COMPONENTS



GENITAL COMPONENTS

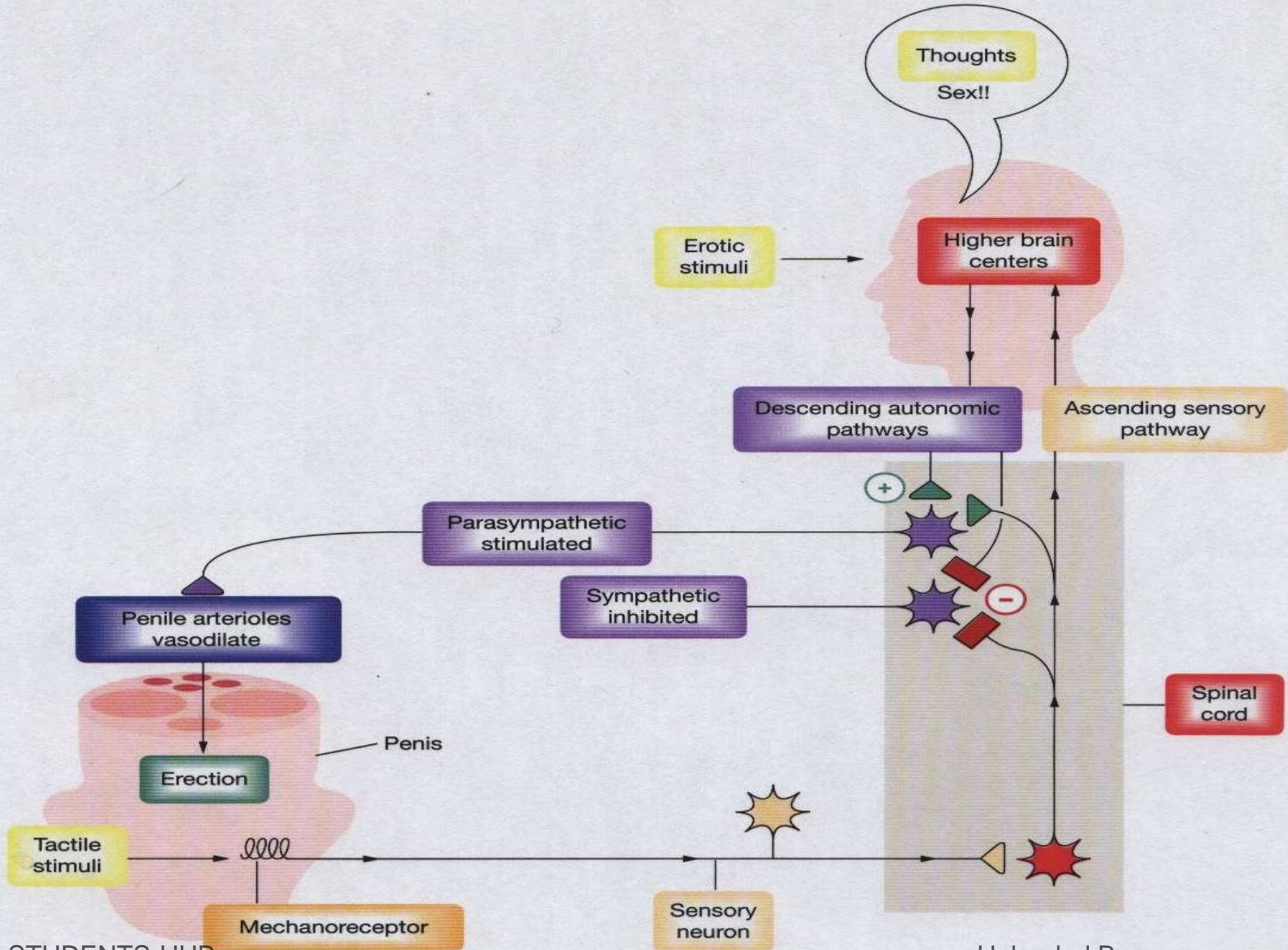


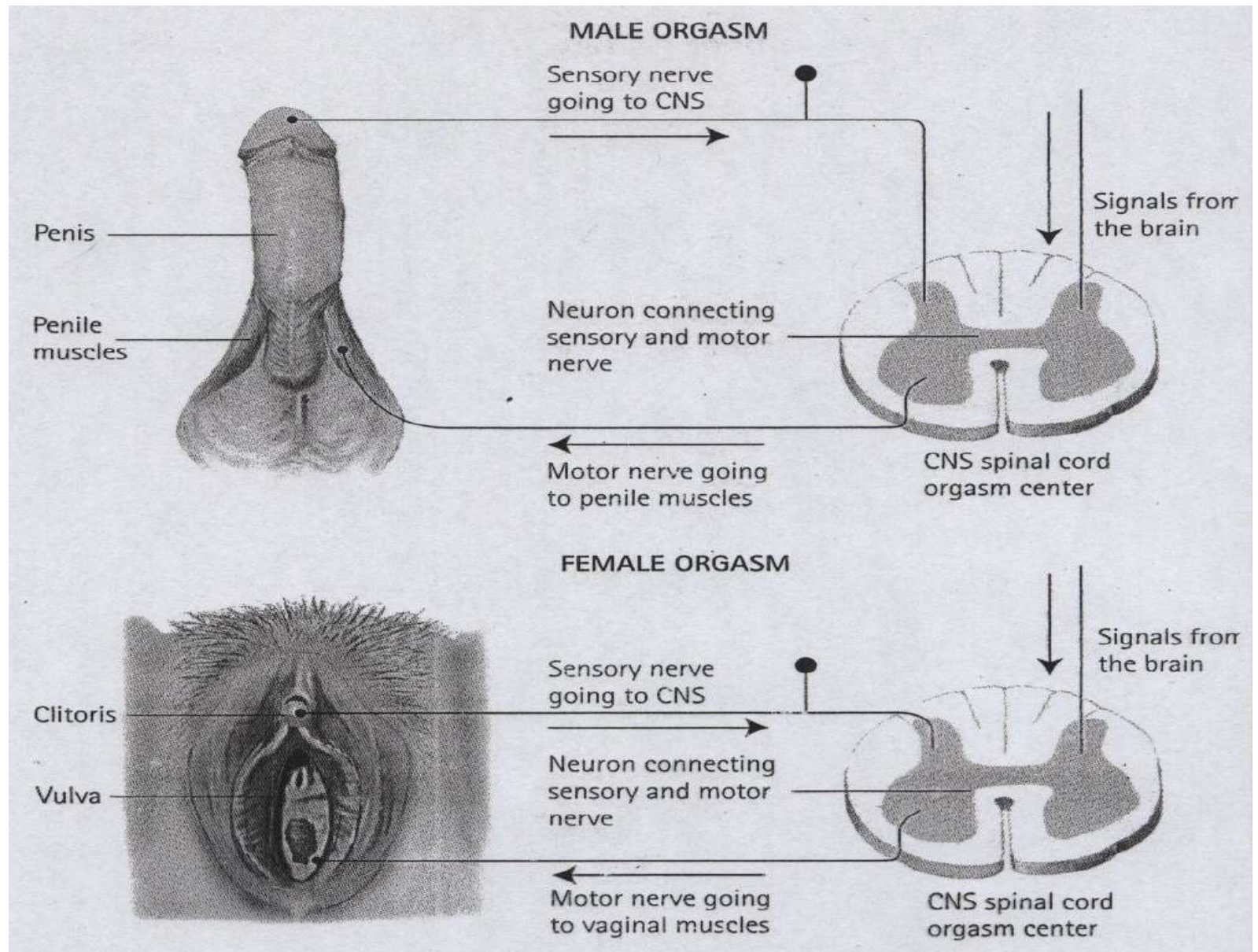
(a)



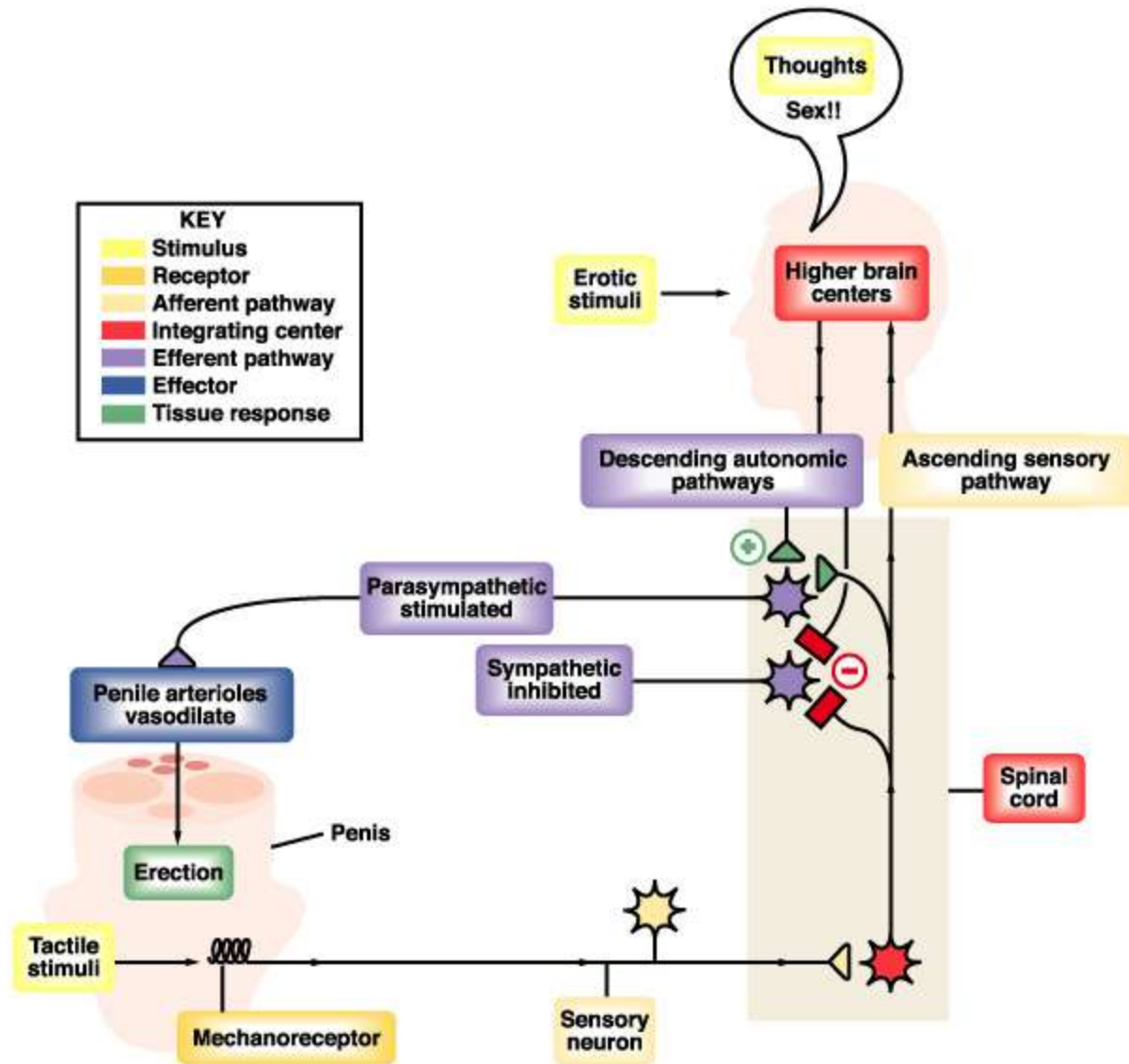
(b)



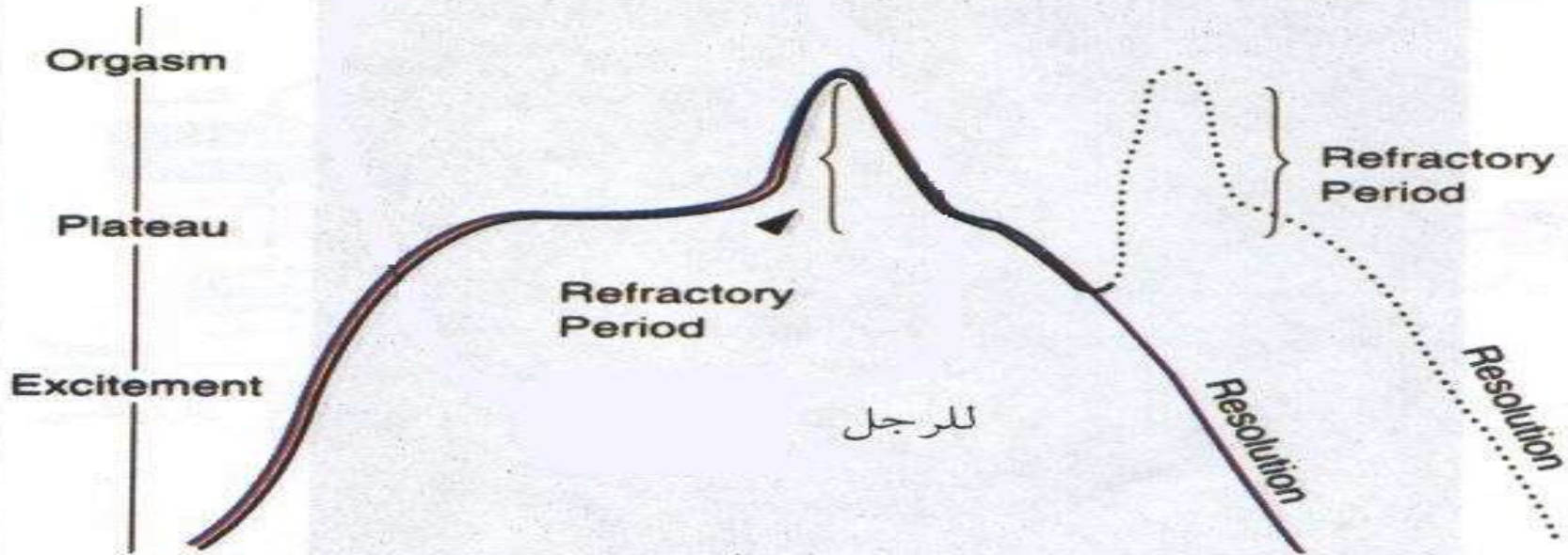
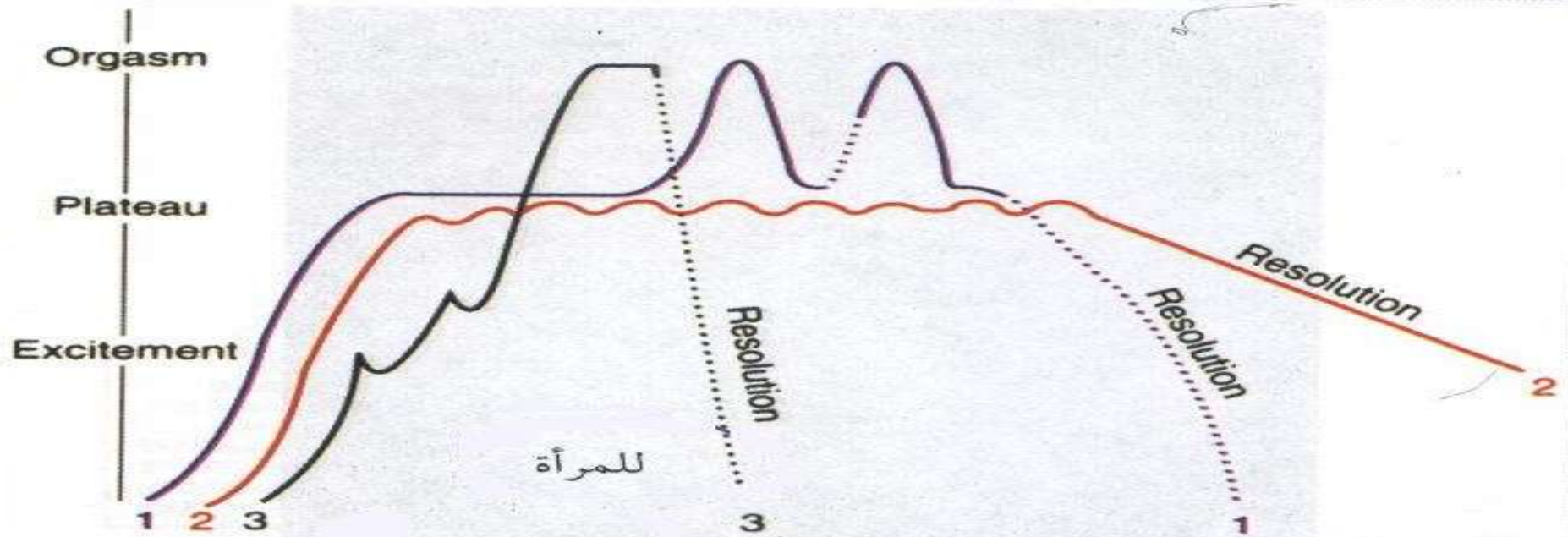




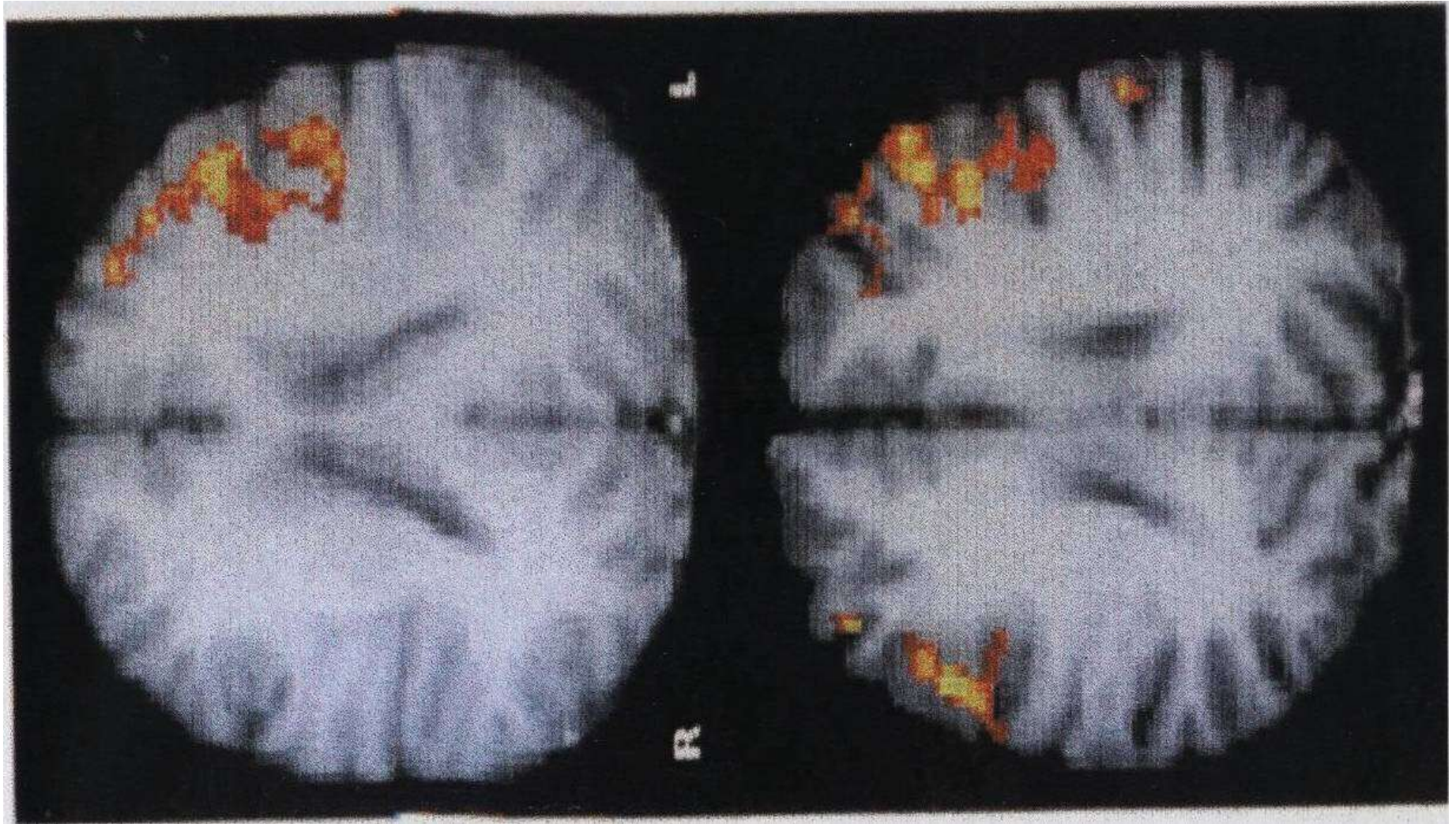




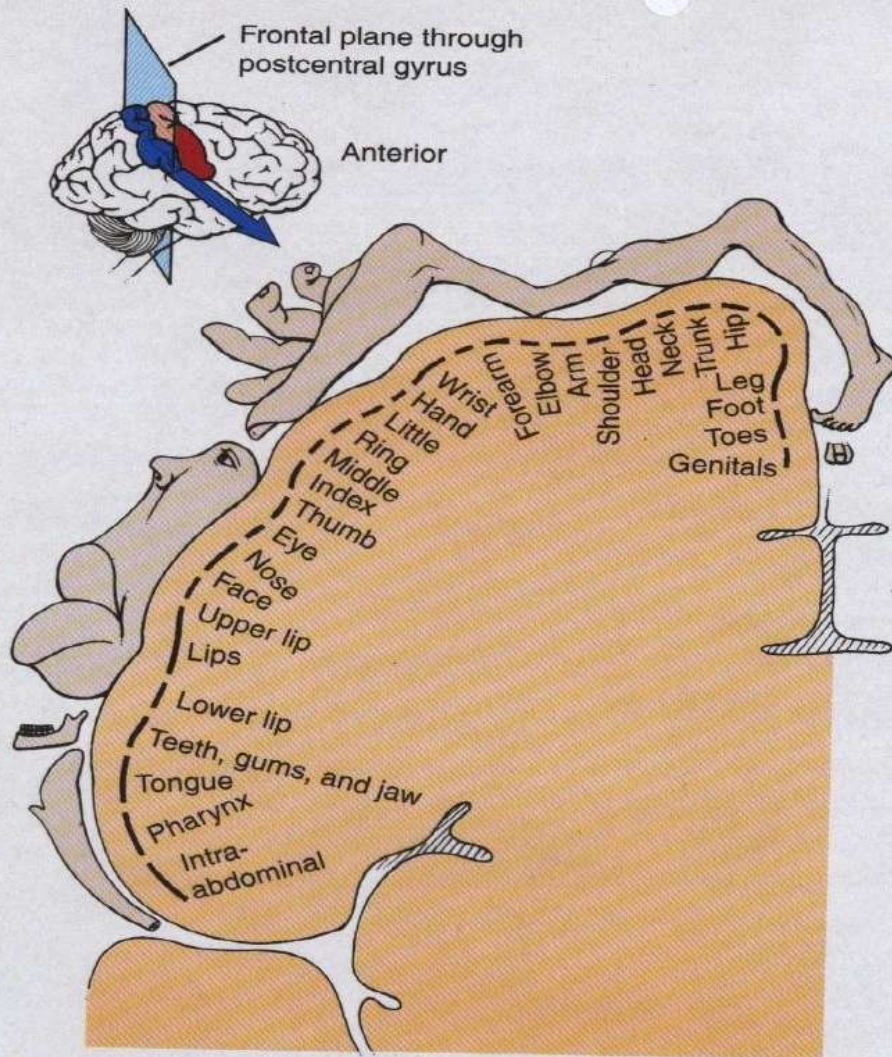




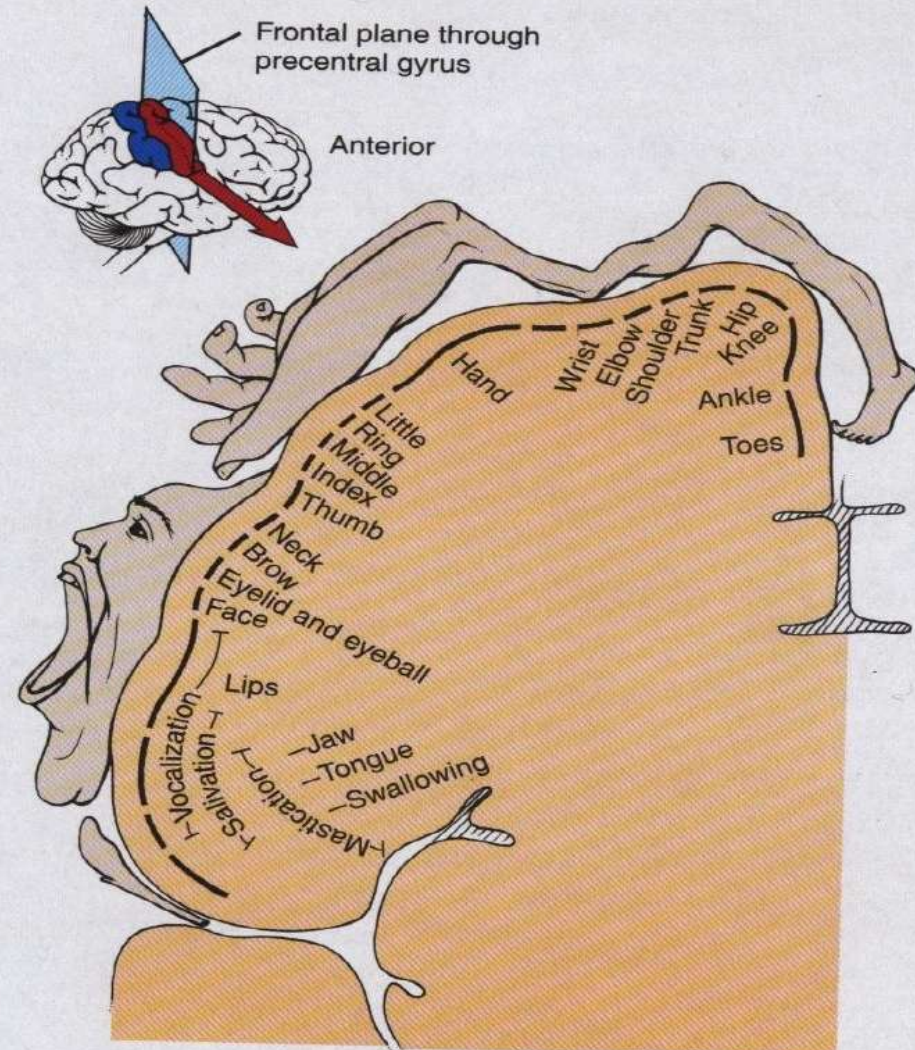








(a) Frontal section of primary somatosensory area in right cerebral hemisphere



(b) Frontal section of primary motor area in right cerebral hemisphere